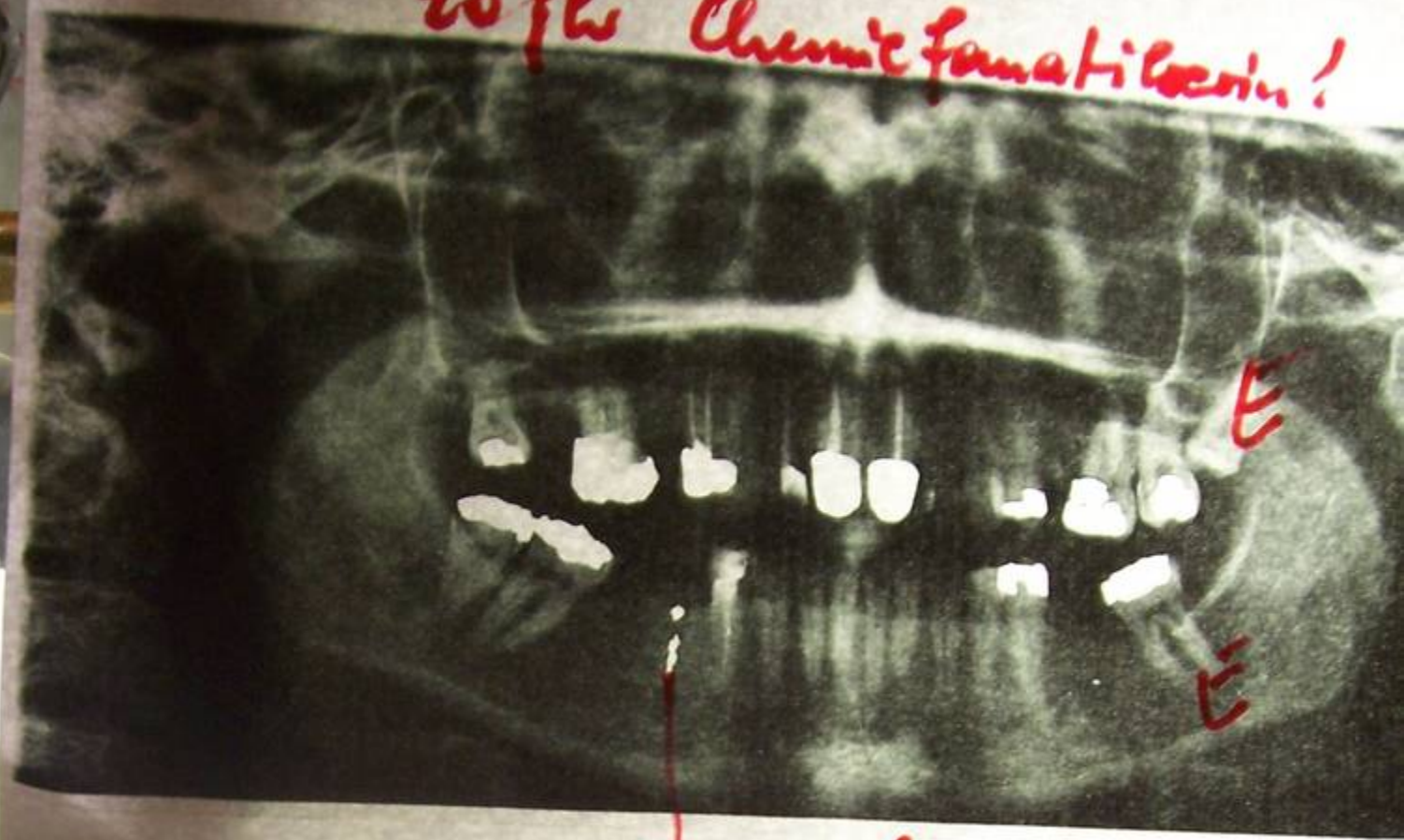


20 jhr Chronische Parodontitis!



E

E

Pfunde 1

Abstr. Amari

Zeit 26 Eiterzahn

