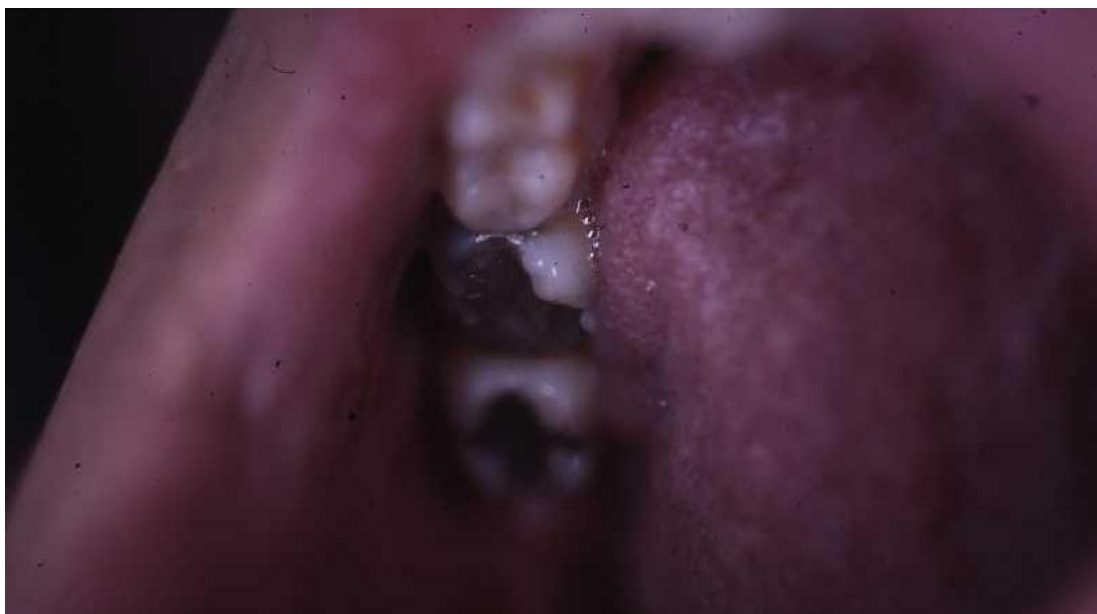
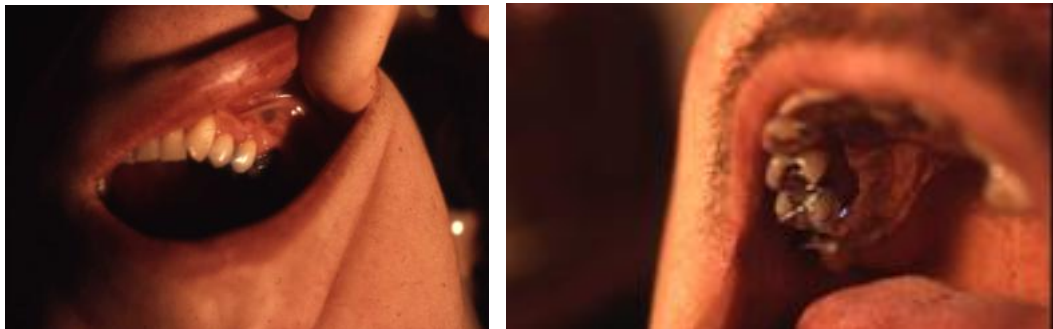
Amalgam

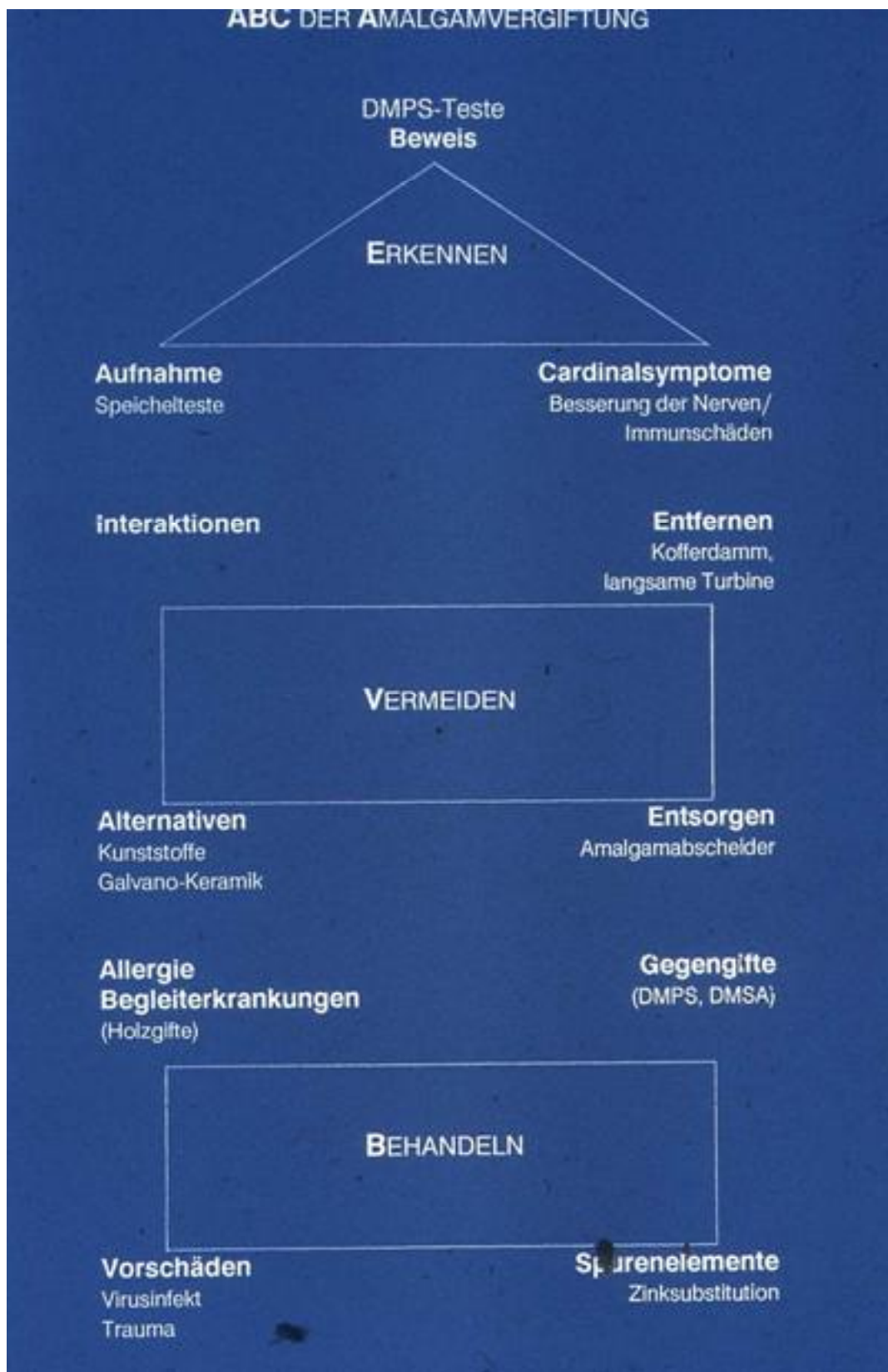
Dentalquecksilber



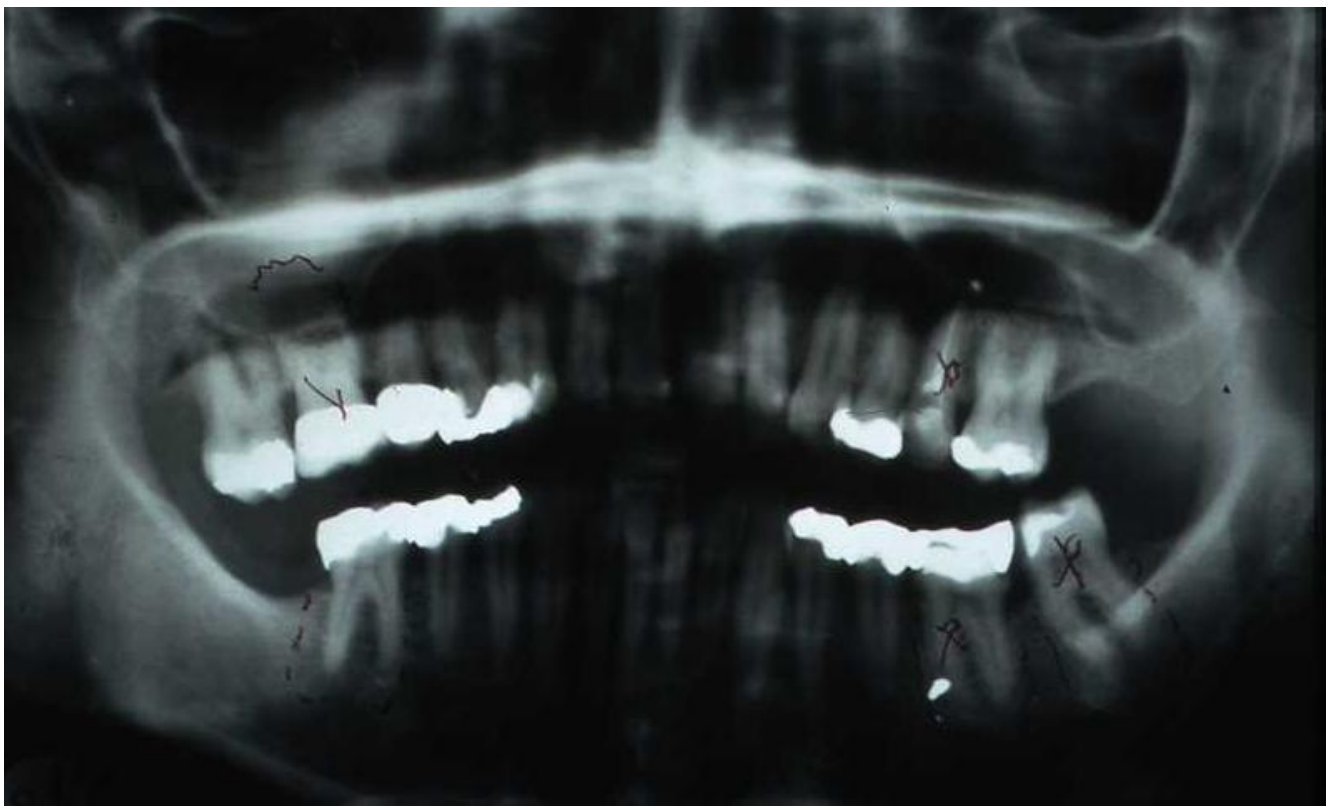
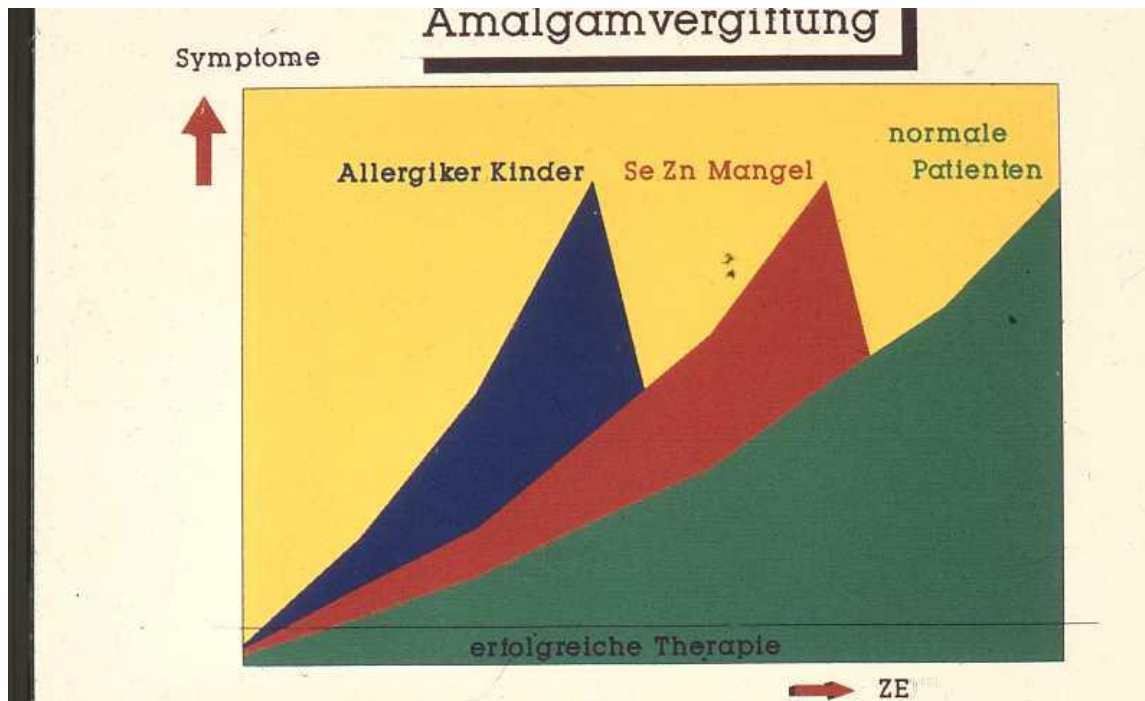
Amalgame



Amalgam

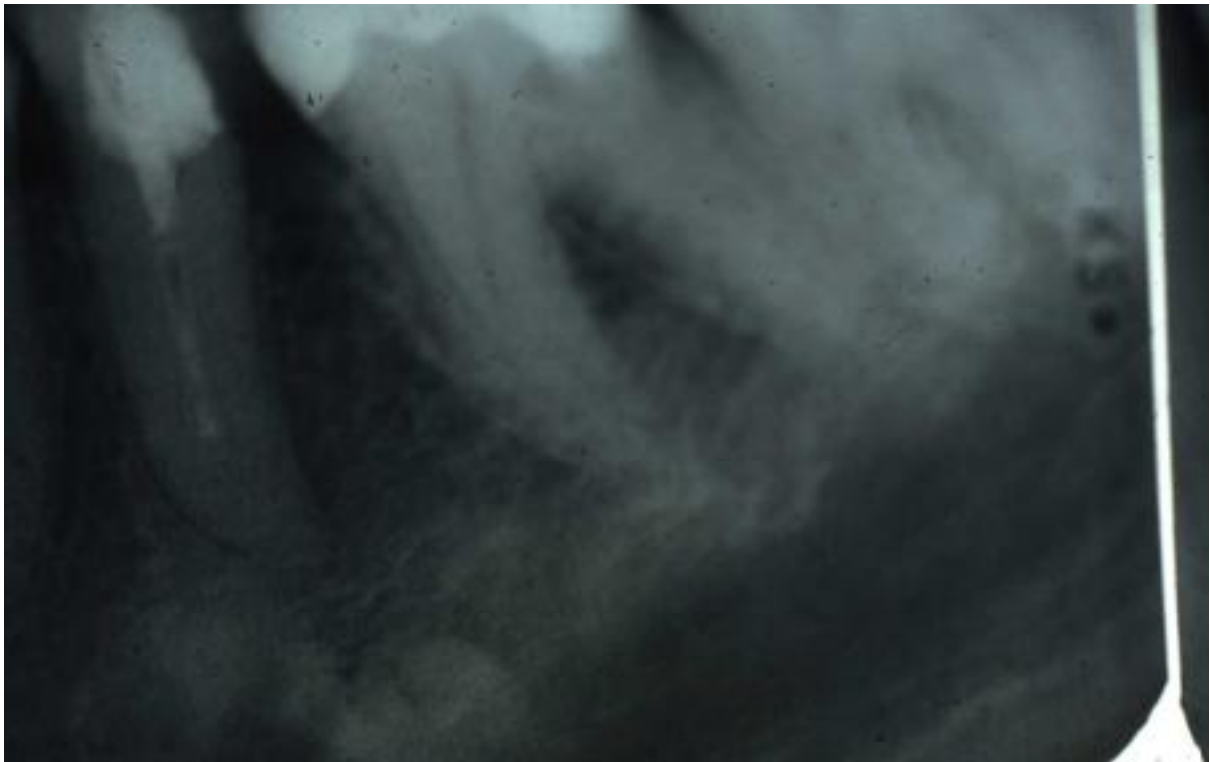
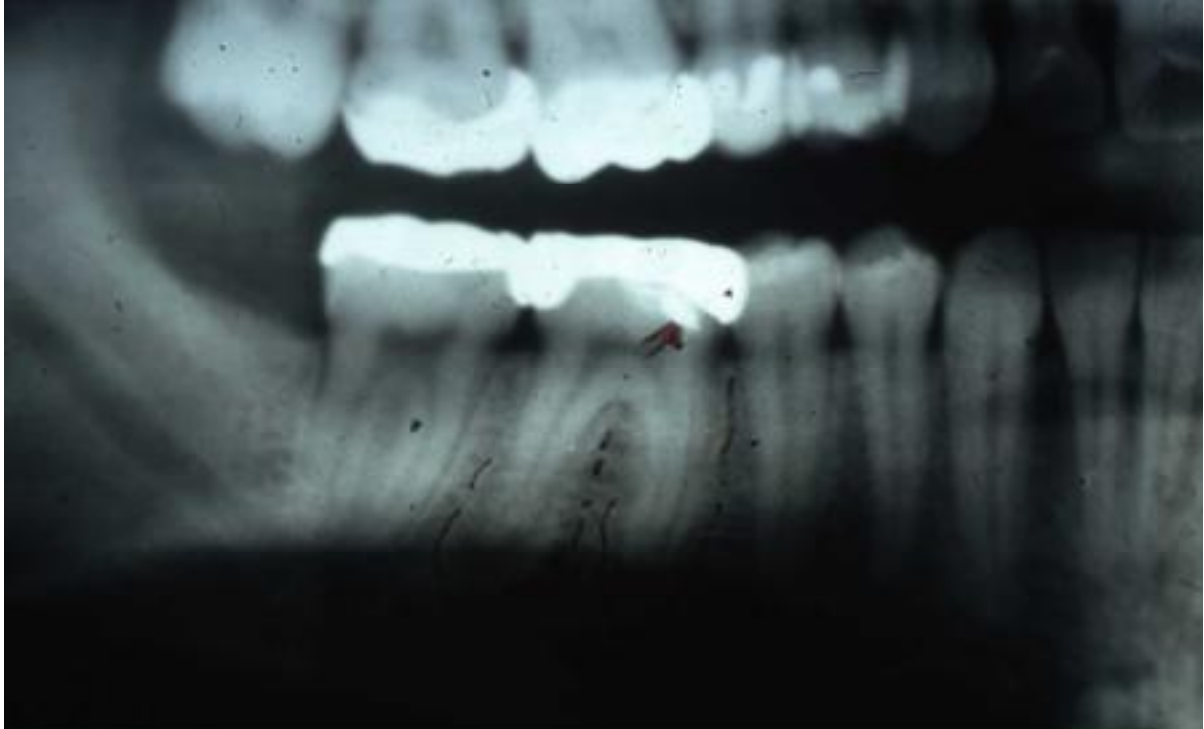

Amalgam

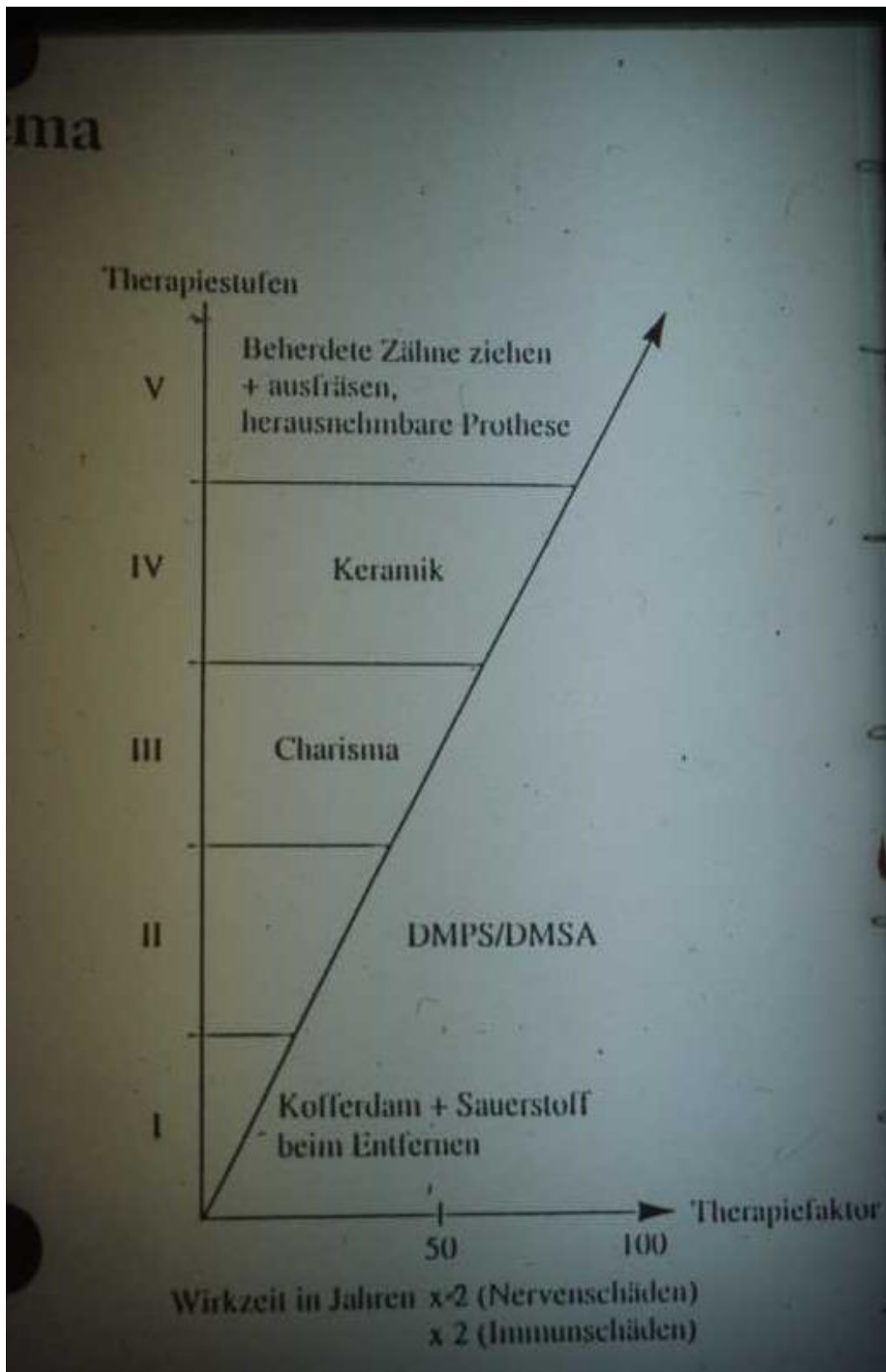


Amalgam

Amalgam perlschnurartig um die Zahnwurzel

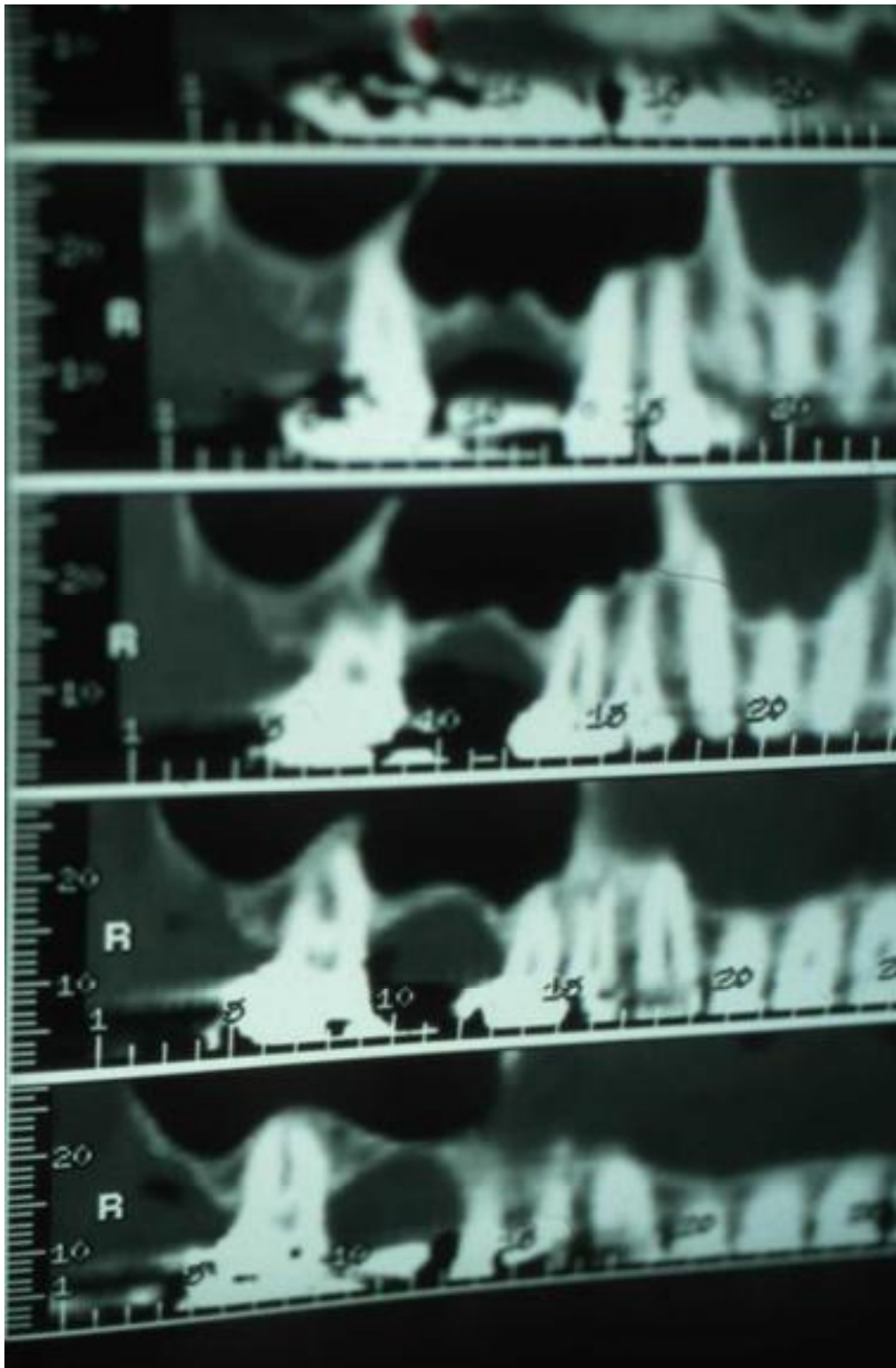


Amalgam



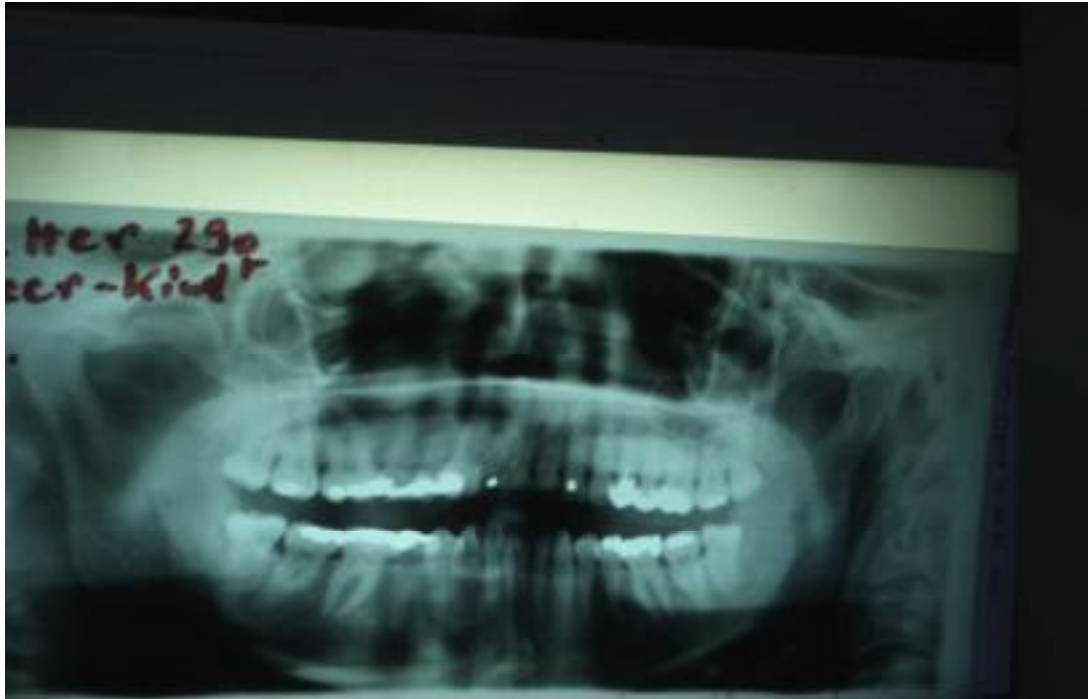
Amalgam

Amalgam Zahnwurzel

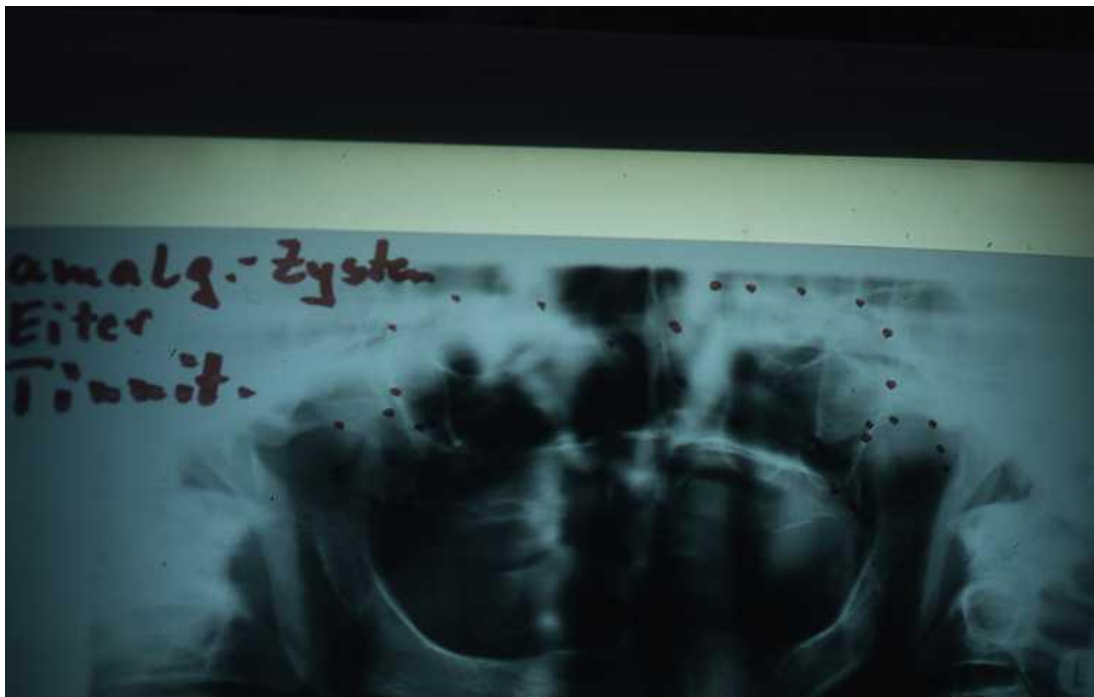


Amalgam

Mutter, 29 Jhr., Feer-Kind

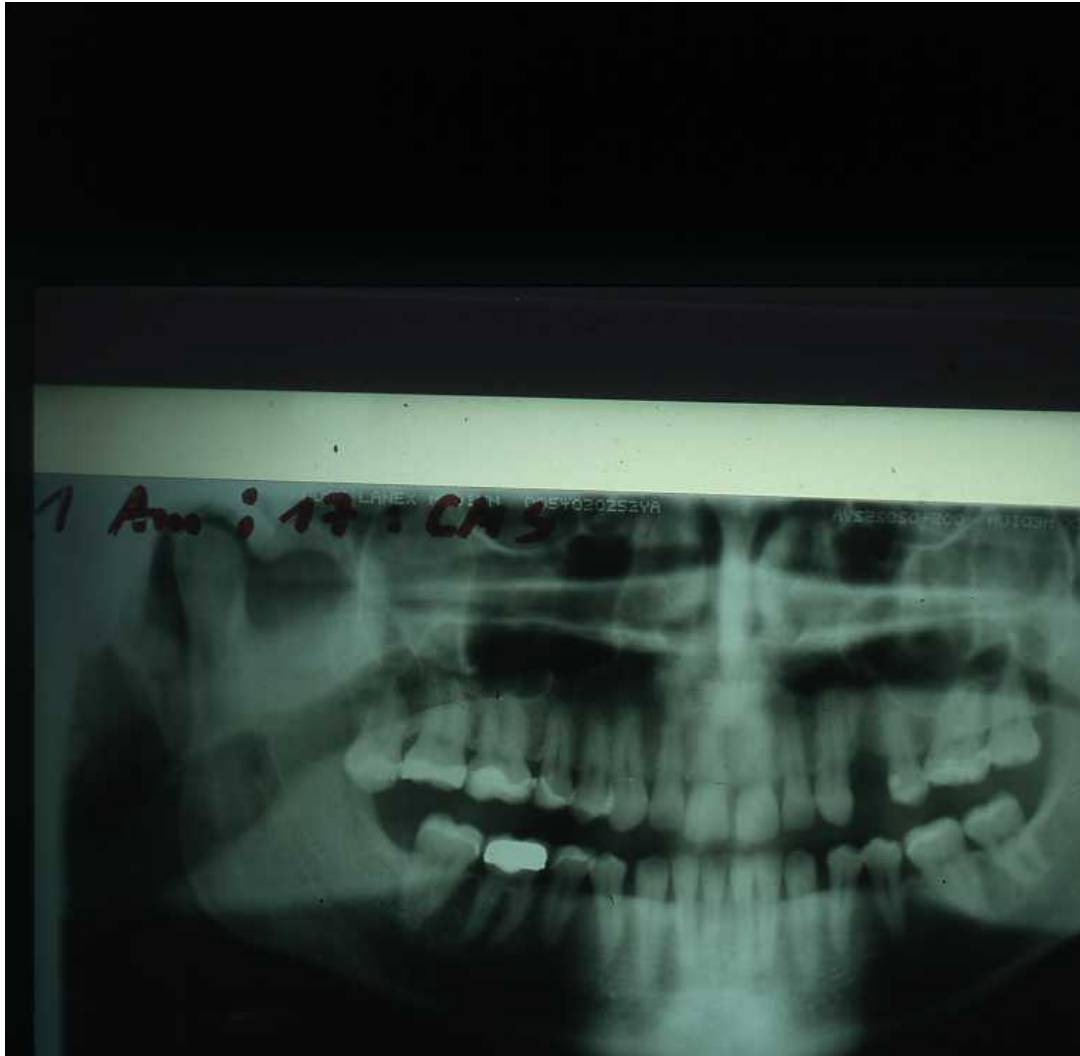

Amalgam-Zysten, Eiter

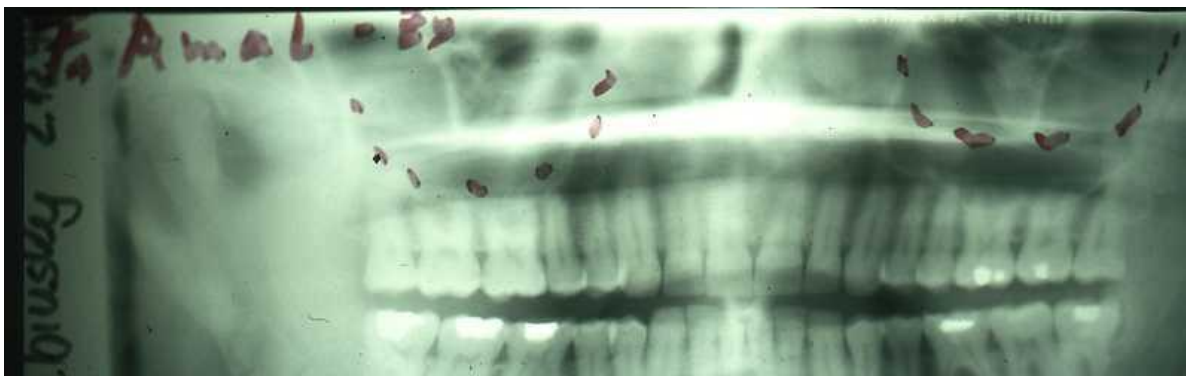


Amalgam

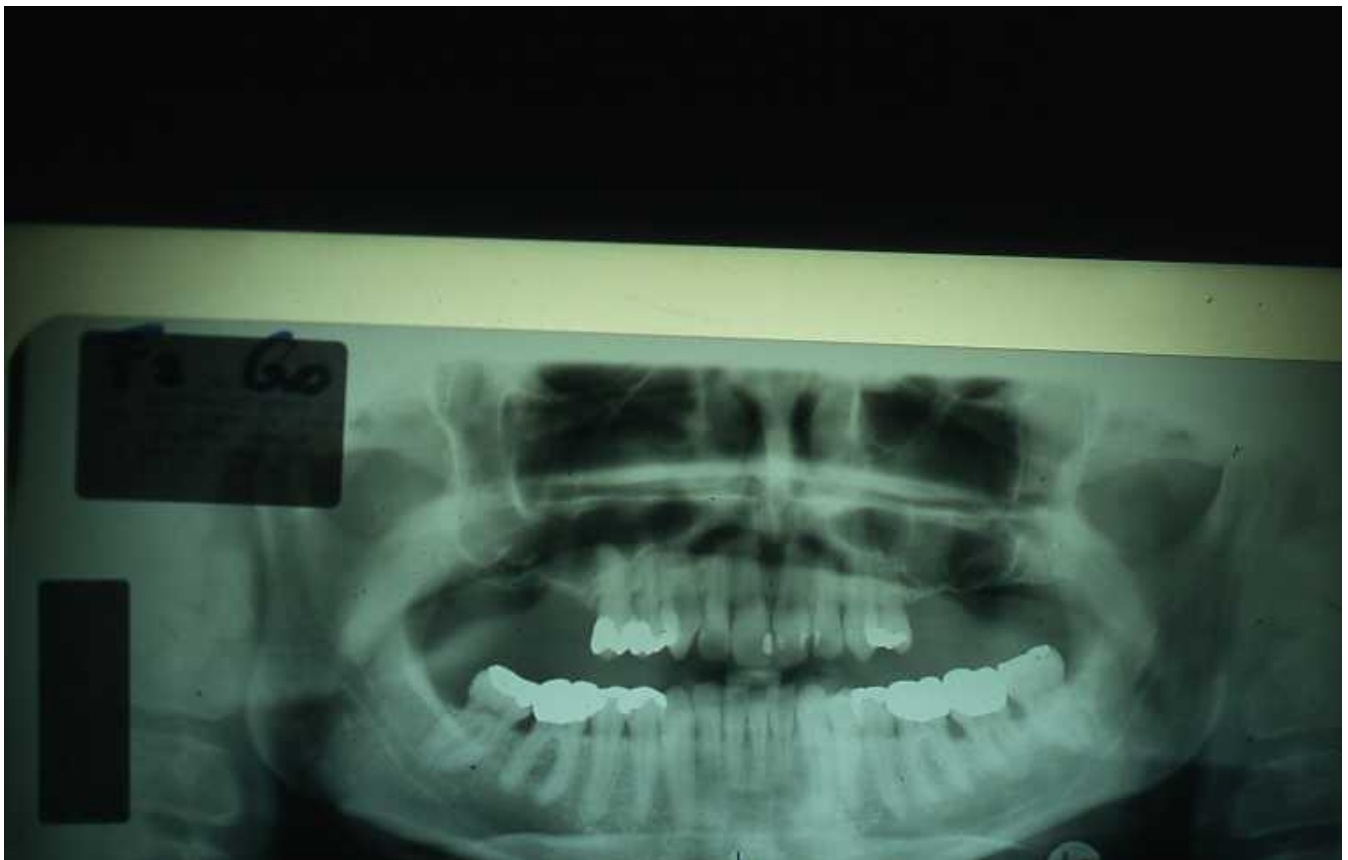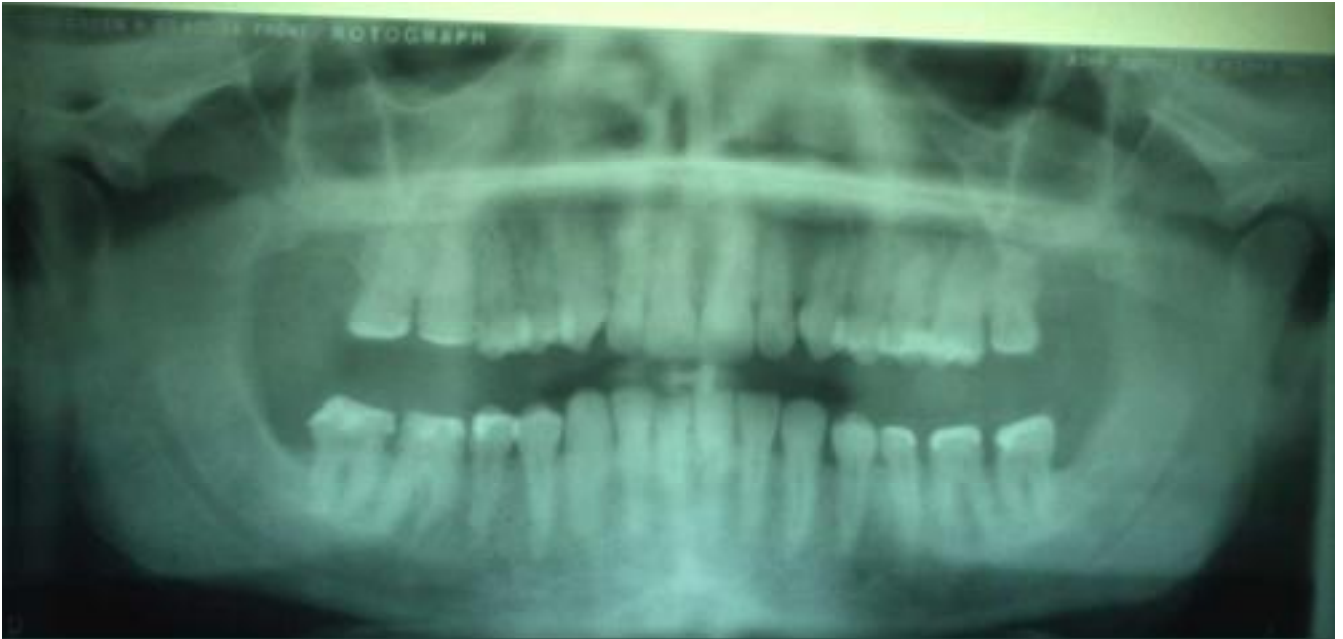1 Amalgam, 17 Jhr., Chronische Müdigkeit (CMS)



Amalgam-Zysten Oberkiefer

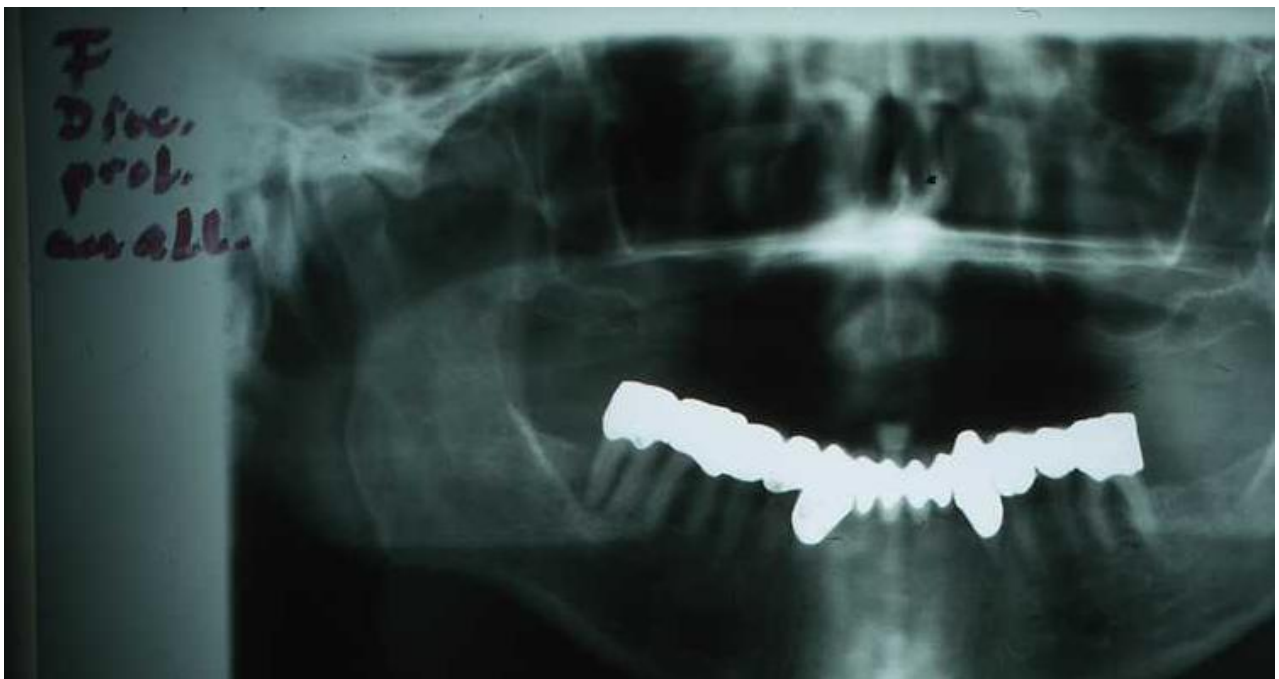
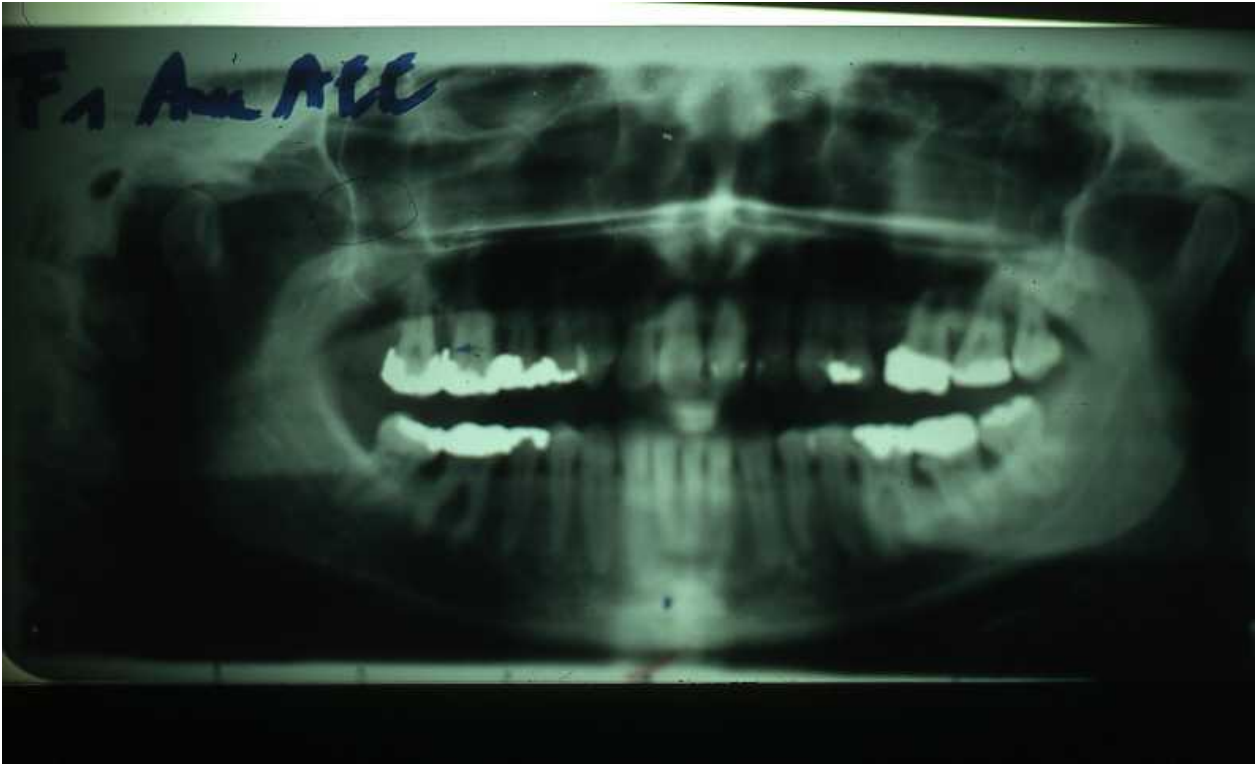
Amalgam



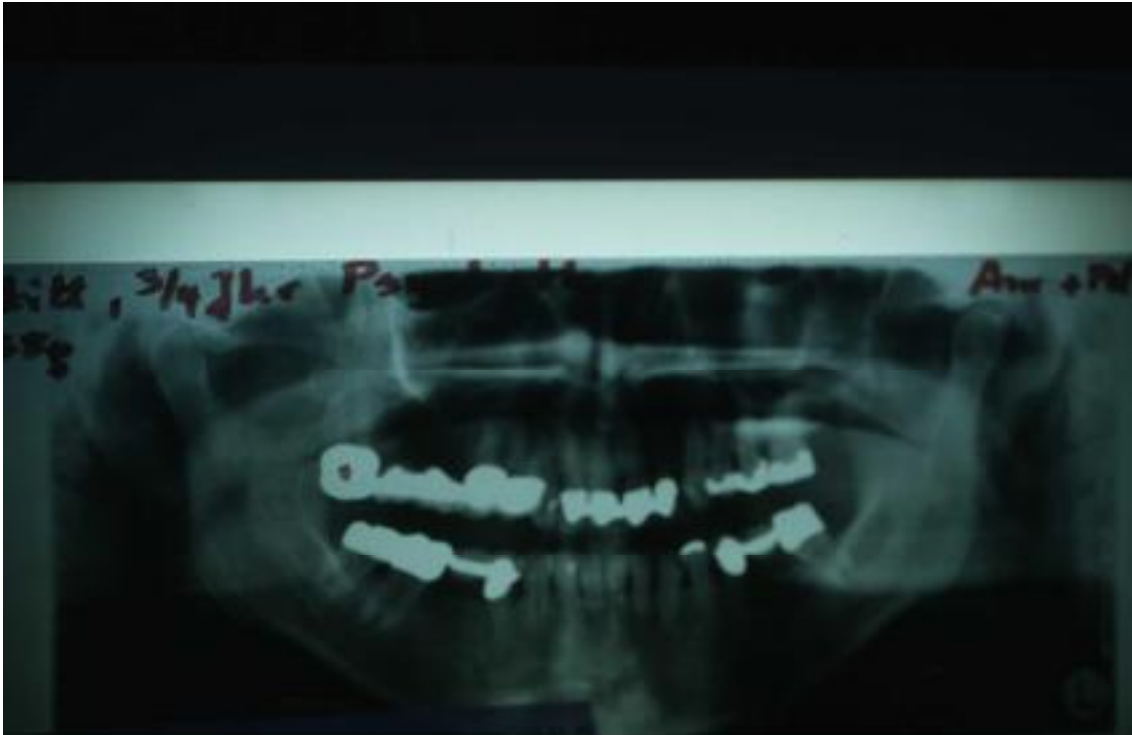Amalgam

Amalgamallergie

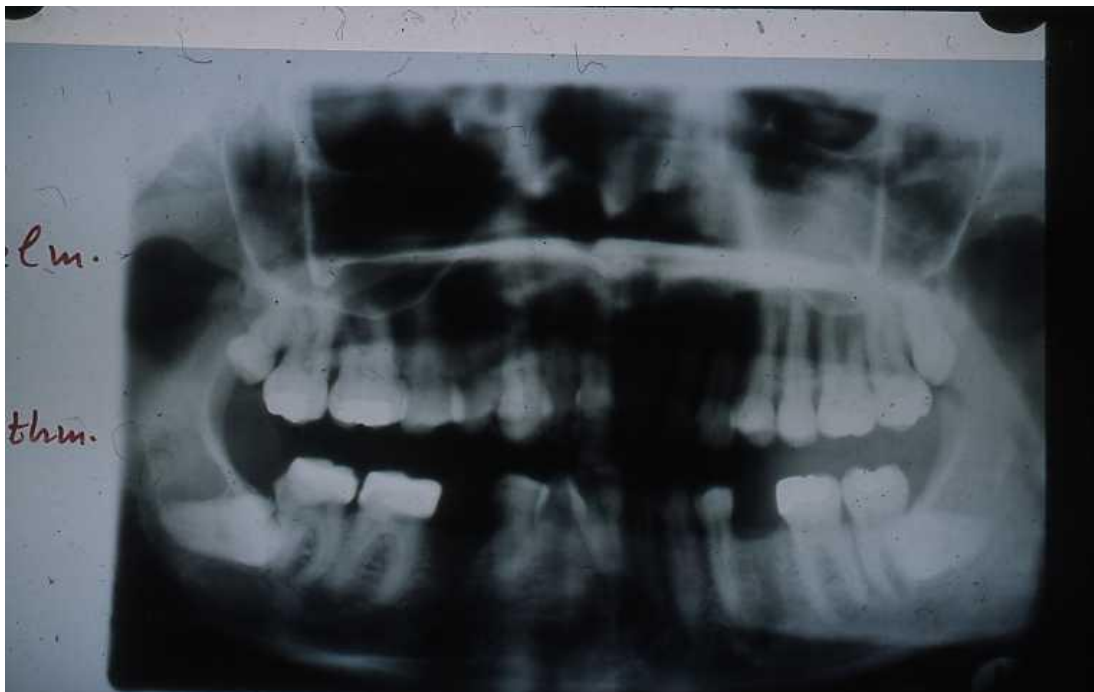

Amalgam

Amalgam + Palladium, $\frac{3}{4}$ Jahr Psychiatrie

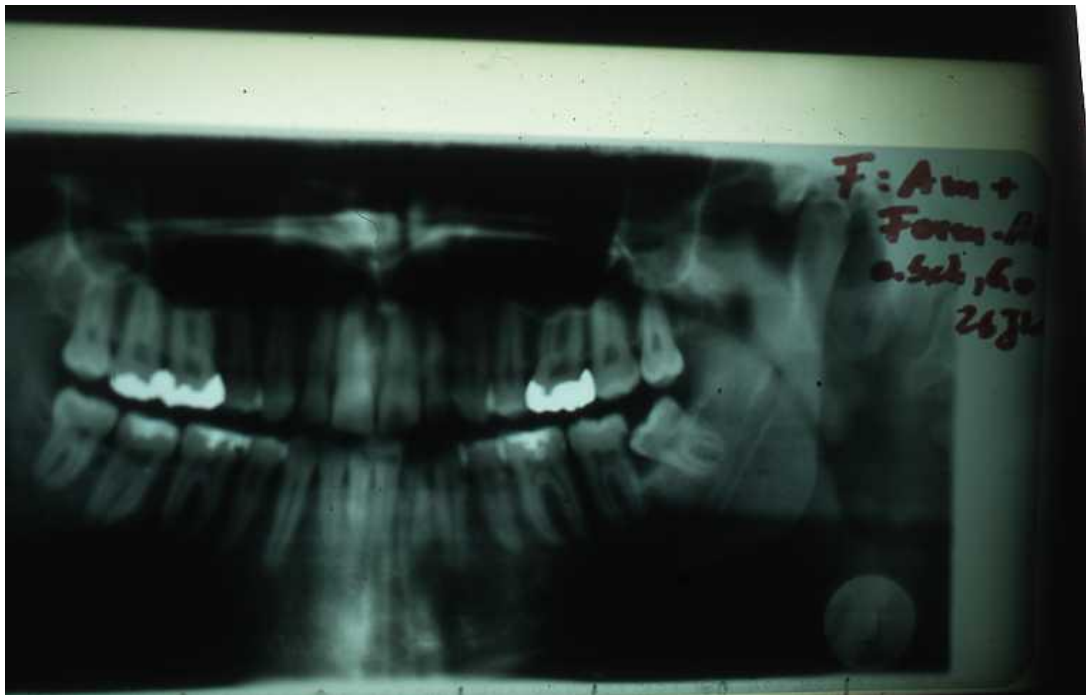
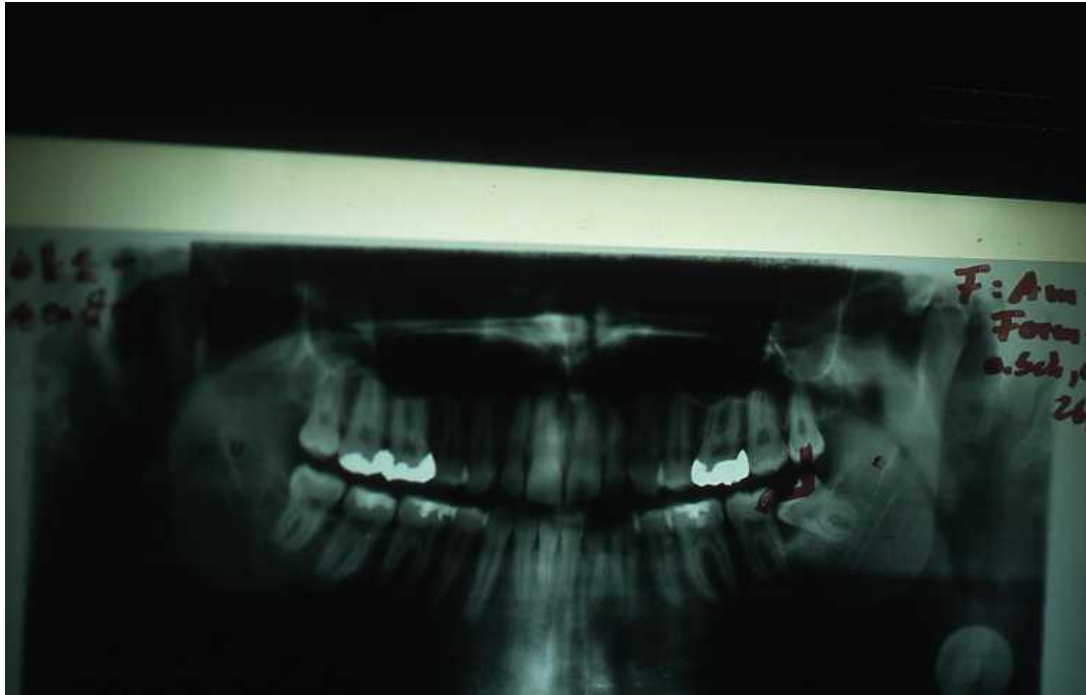


Amalgam + Herzrhythmusstörungen



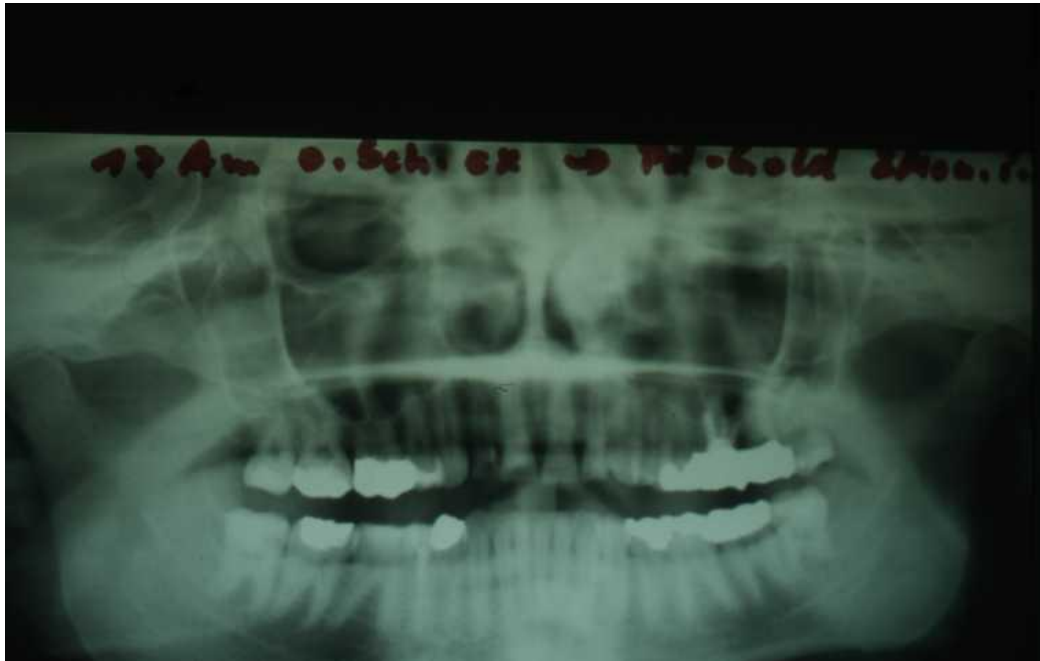Amalgam

Fehler: Amalgam ohne Schutz entfernt, 26 Jhr.

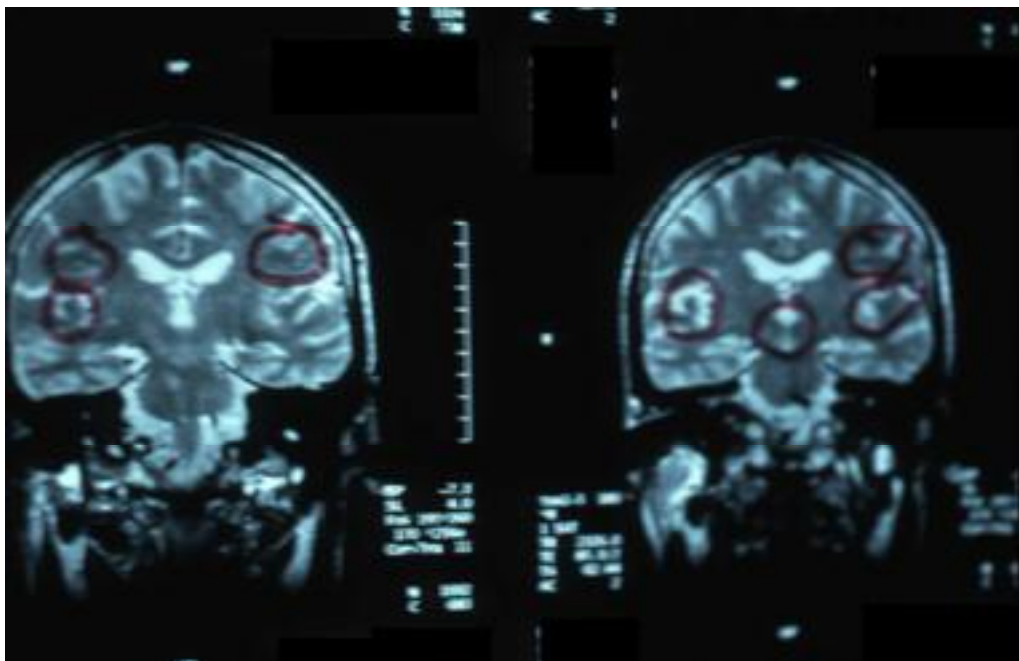


Amalgam

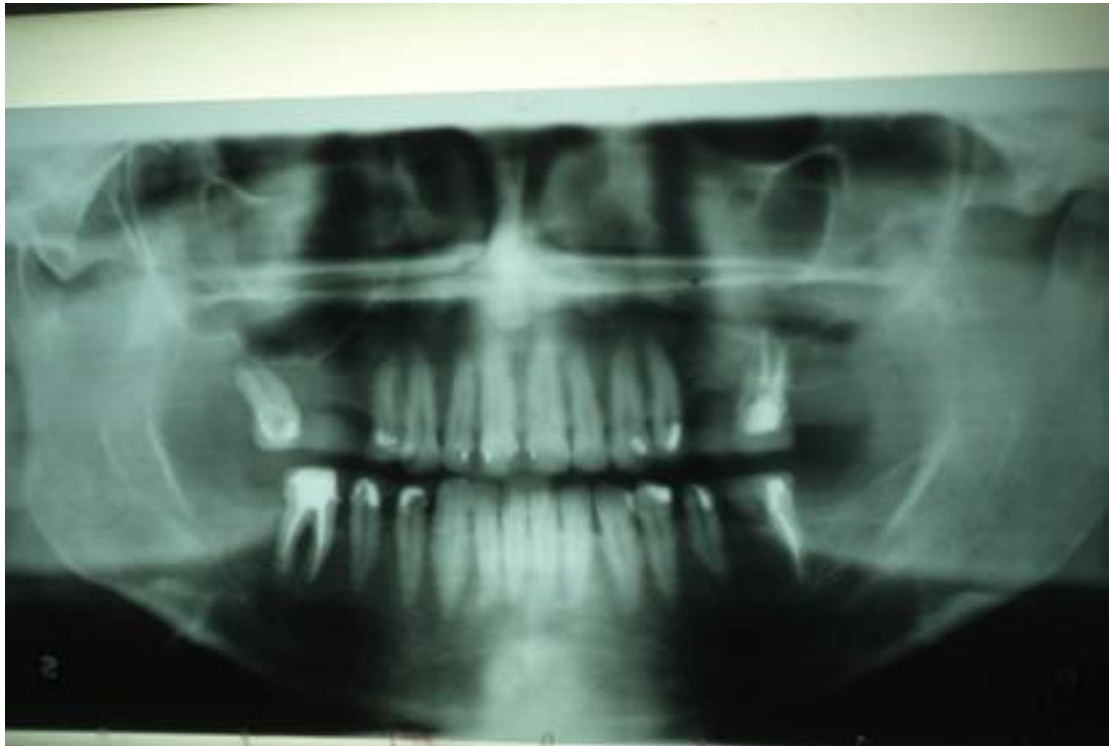Fehler: 17 Amalgame ohne Schutz entfernt, danach Palladium-Gold-Legierungen



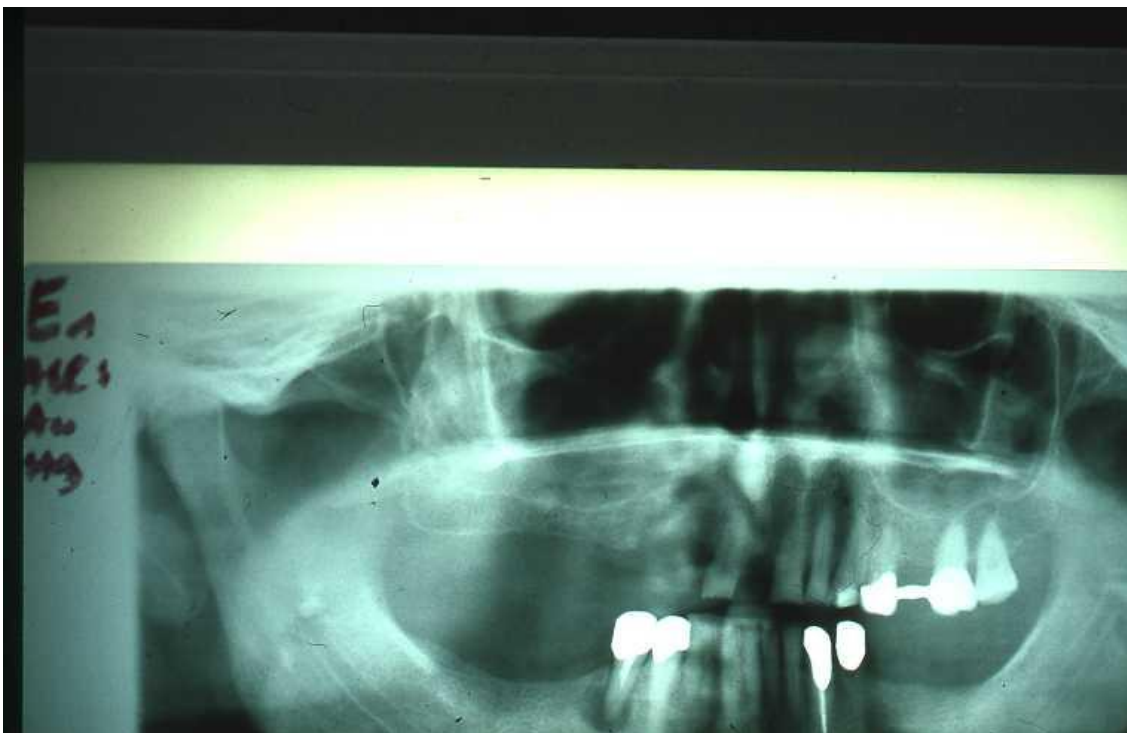
Metallherde im Gehirn



Amalgam

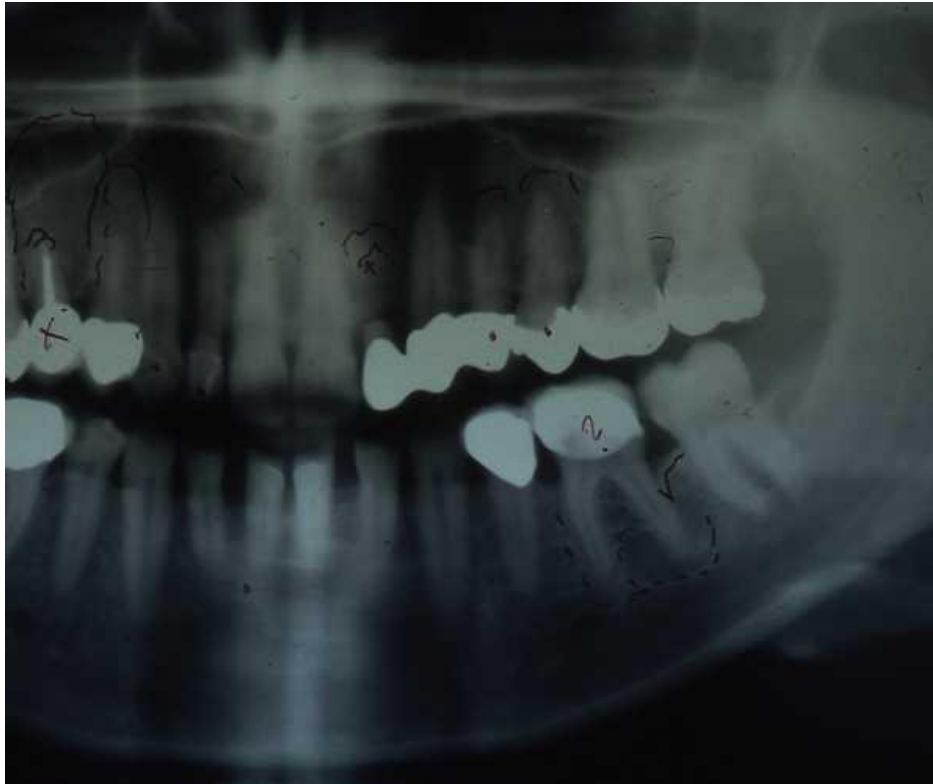


Amalgam- und Goldallergie

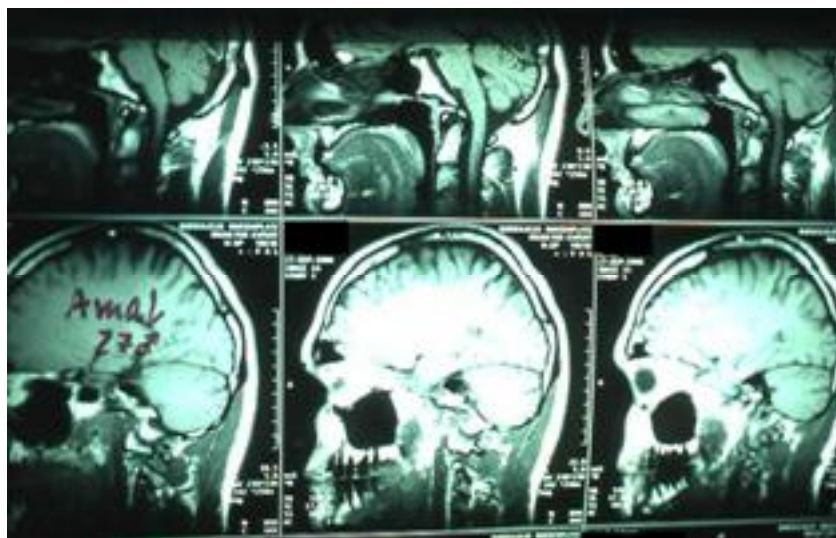


Amalgam

Amalgamreste an den Zahnwurzeln

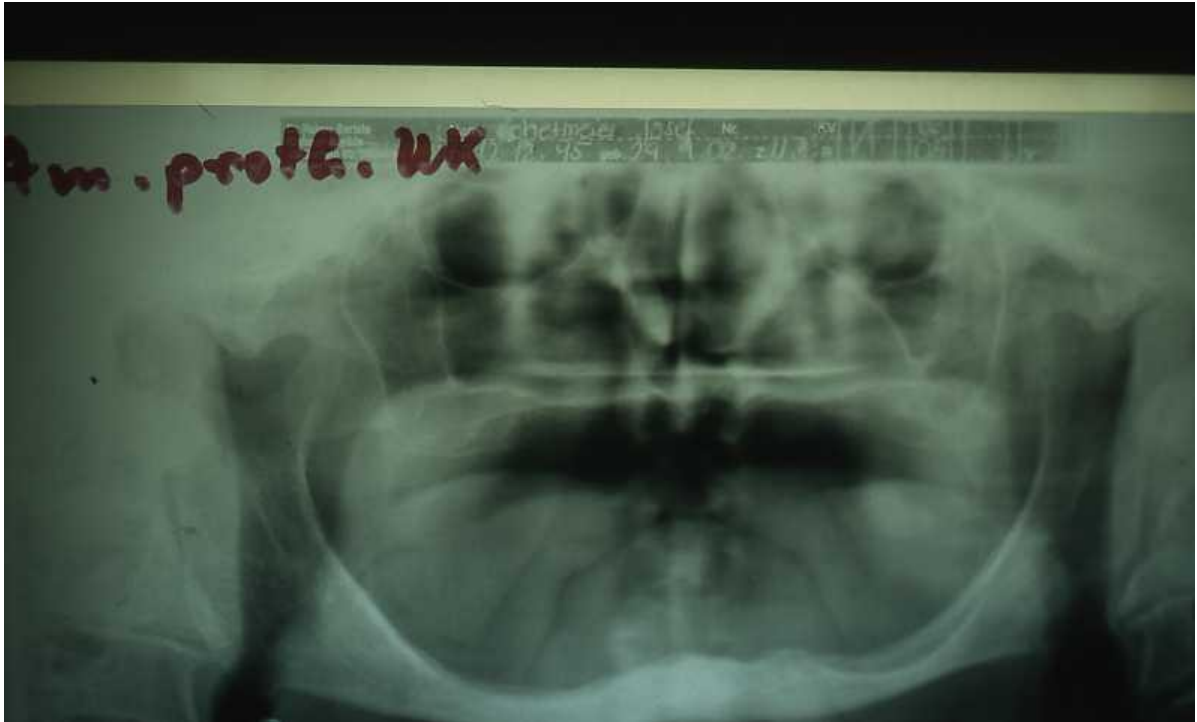

Amalgam, 27 Jahre

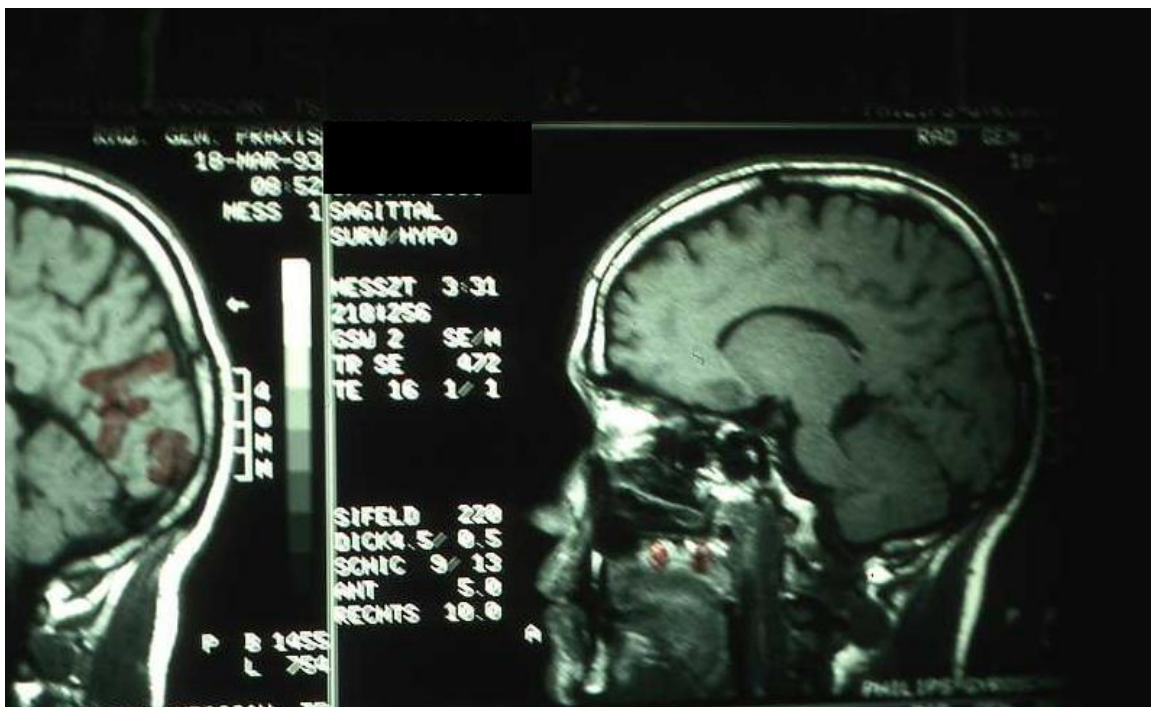


Amalgam

Amalgamprothese Unterkiefer

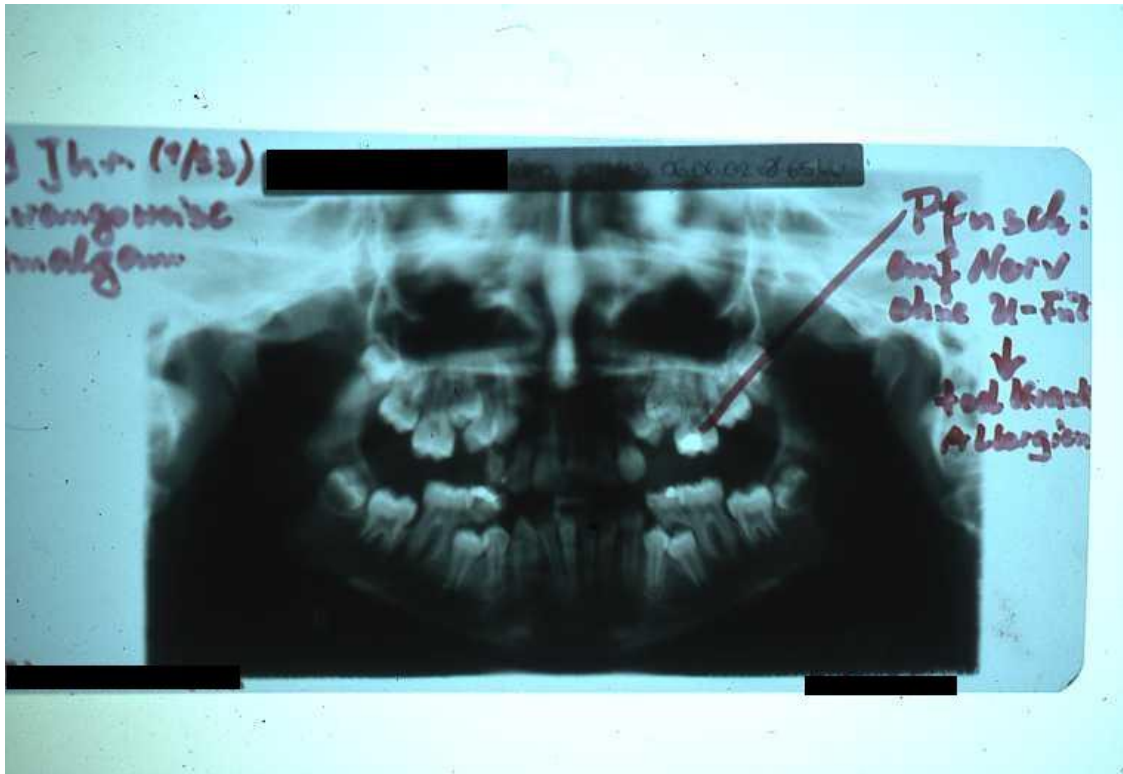


Amalgamreste Oberkiefer



Amalgam

**Pfusch: Amalgam ohne Unterfüllung auf Nerv gestopft –
todkrank, Allergien**



Amalgam in Milchzähnen trotz Widerstand der Mutter, 6 Jhr.

