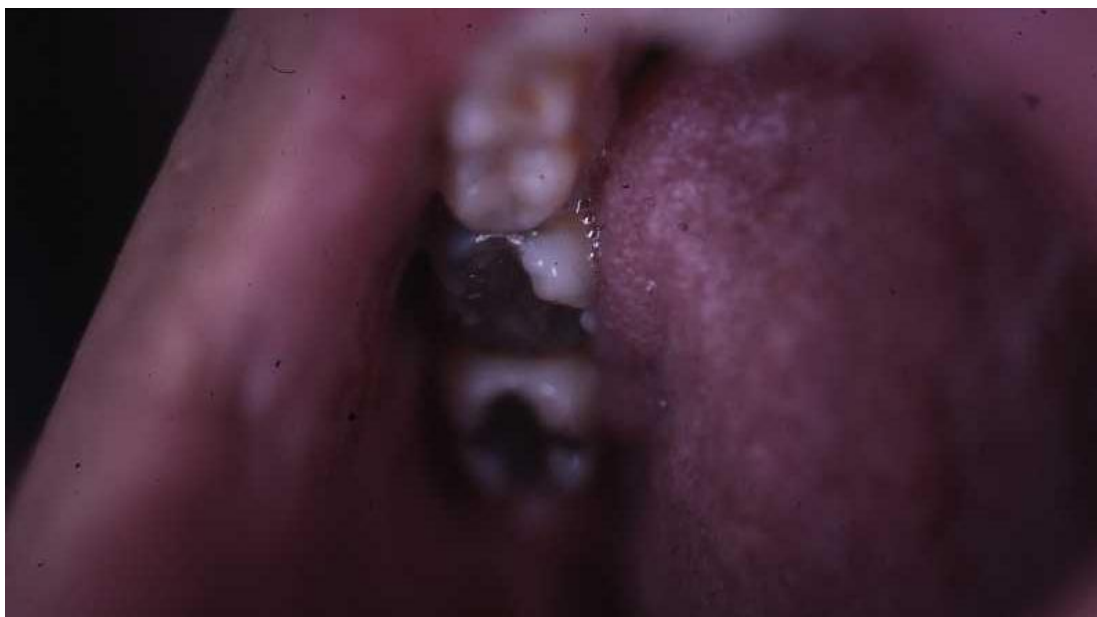
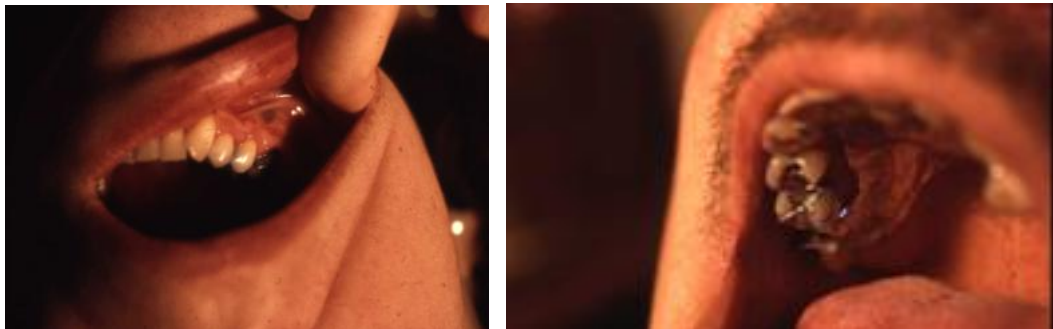
# Amalgam, Prestigeobjekt

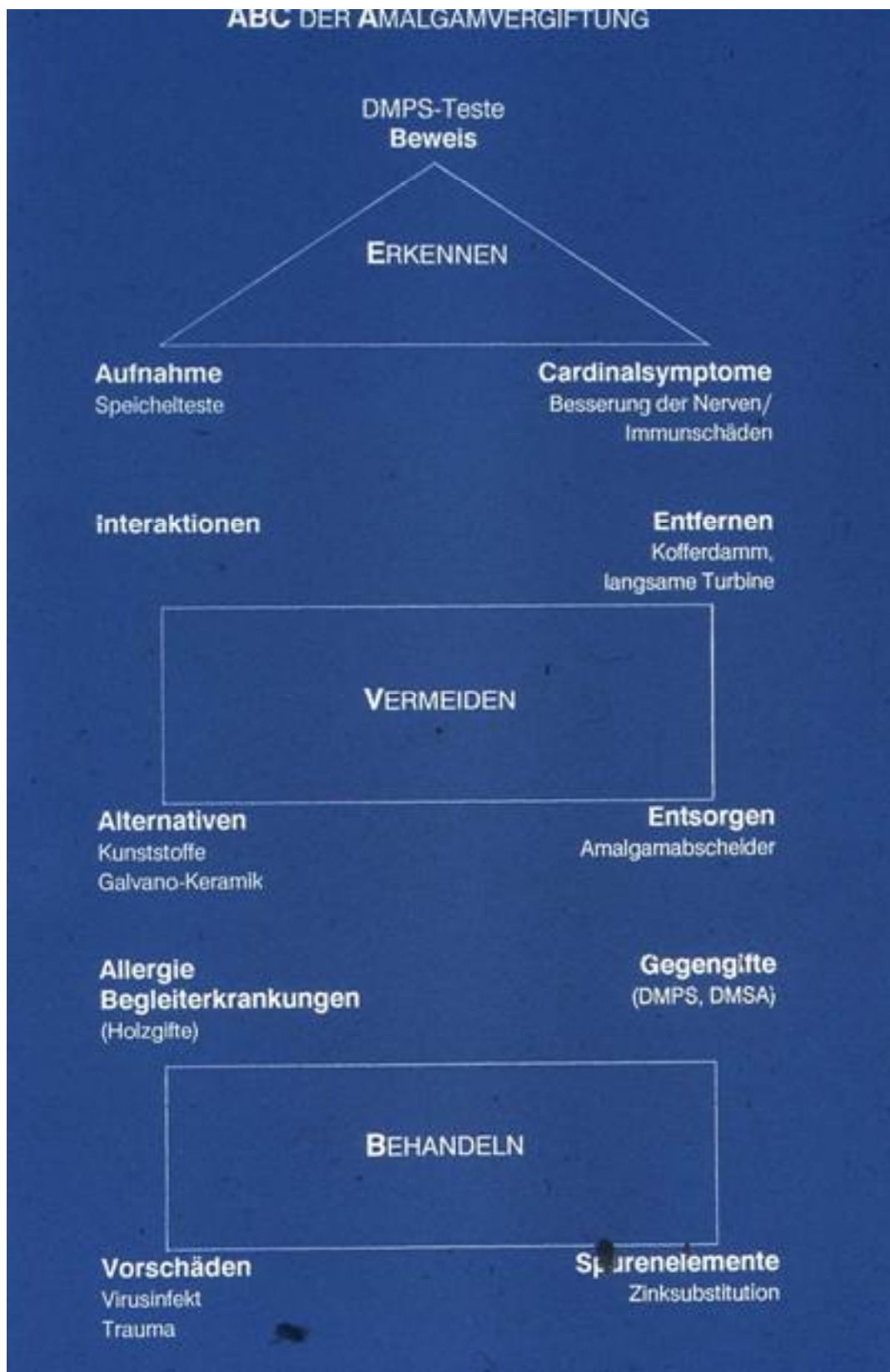
## Dentalquecksilber



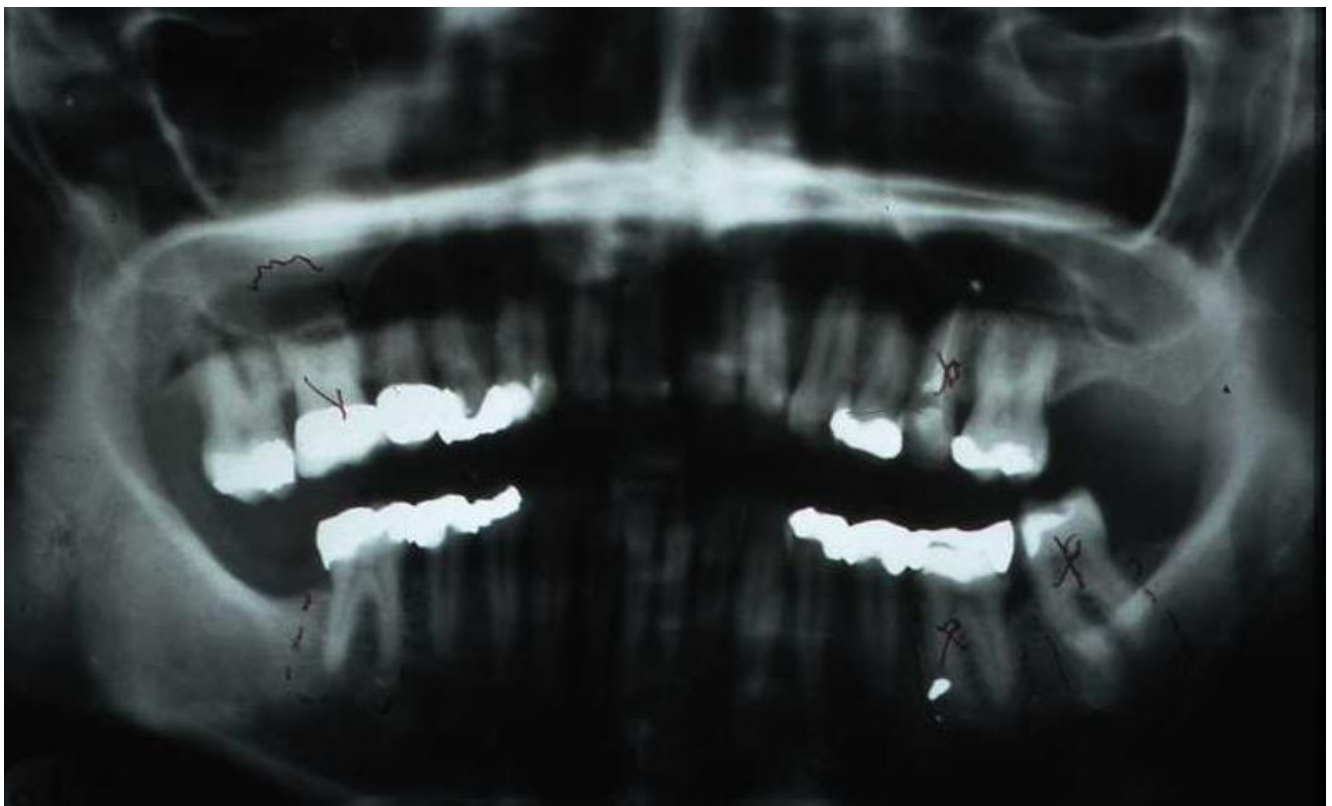
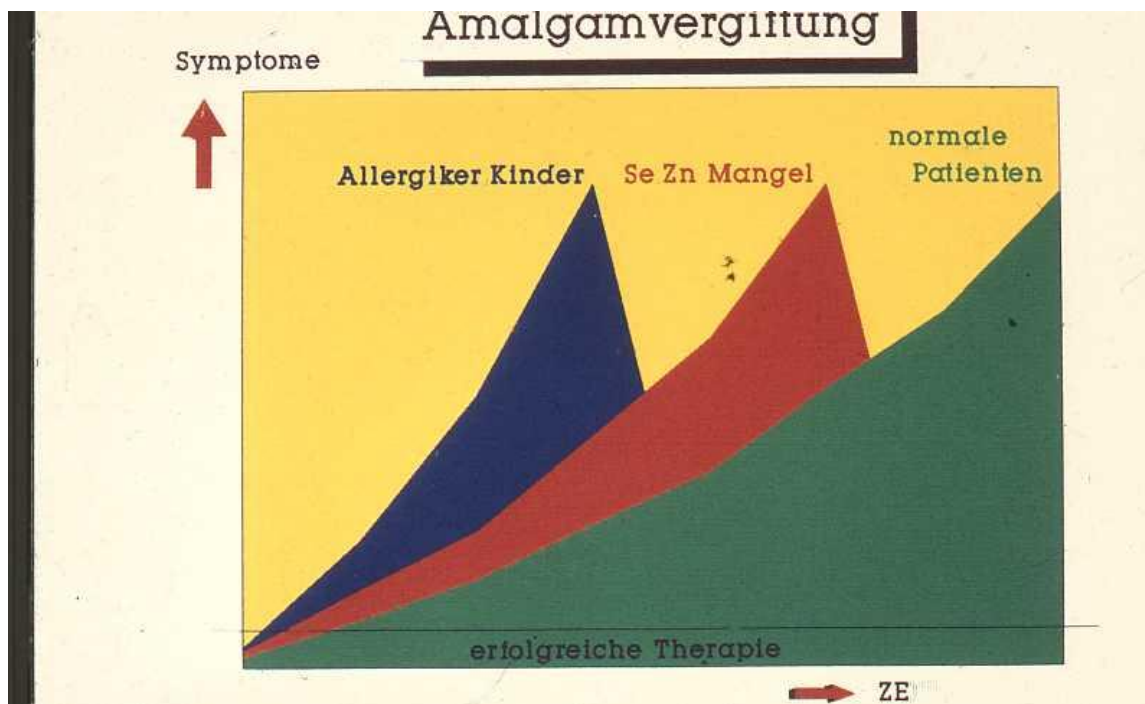
## Amalgame



# Amalgam

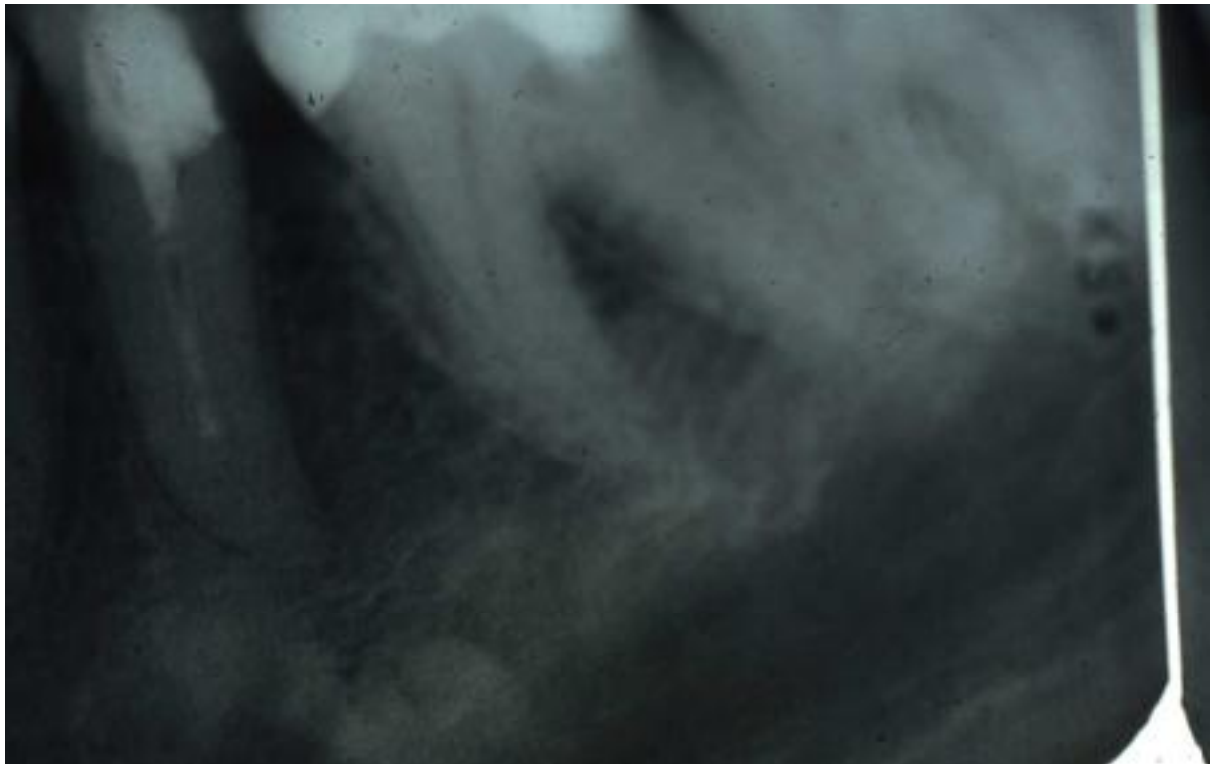
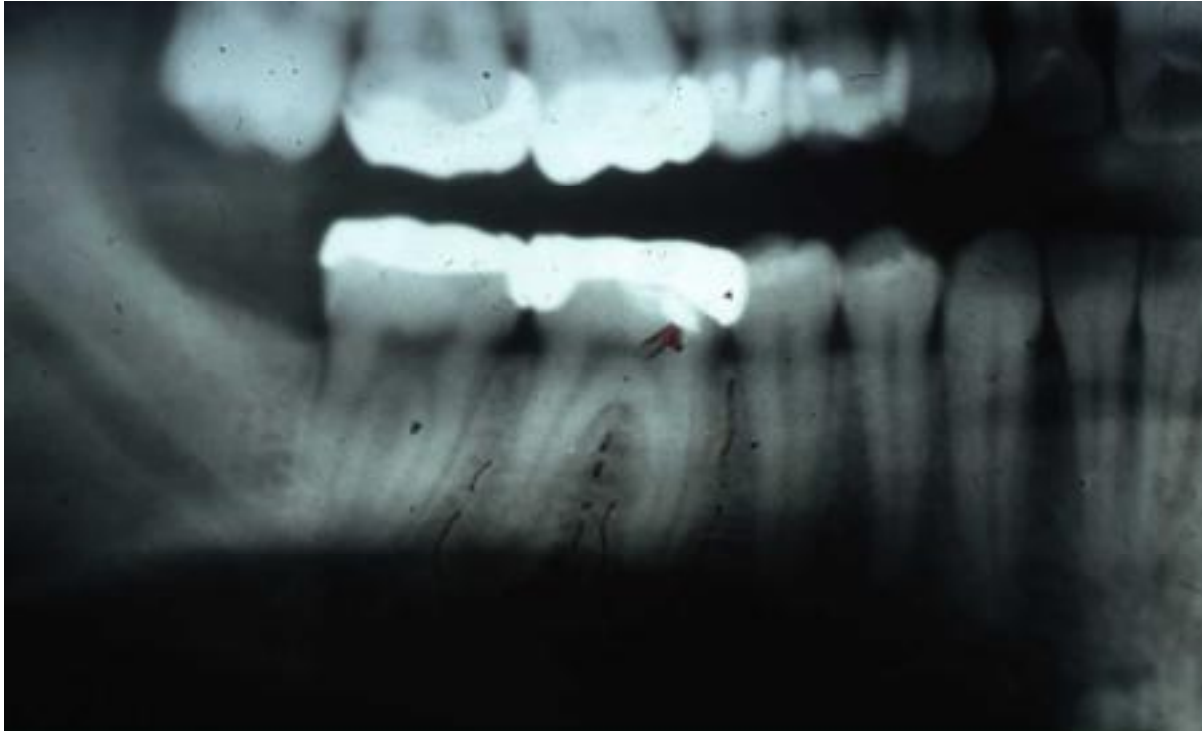

# Amalgam

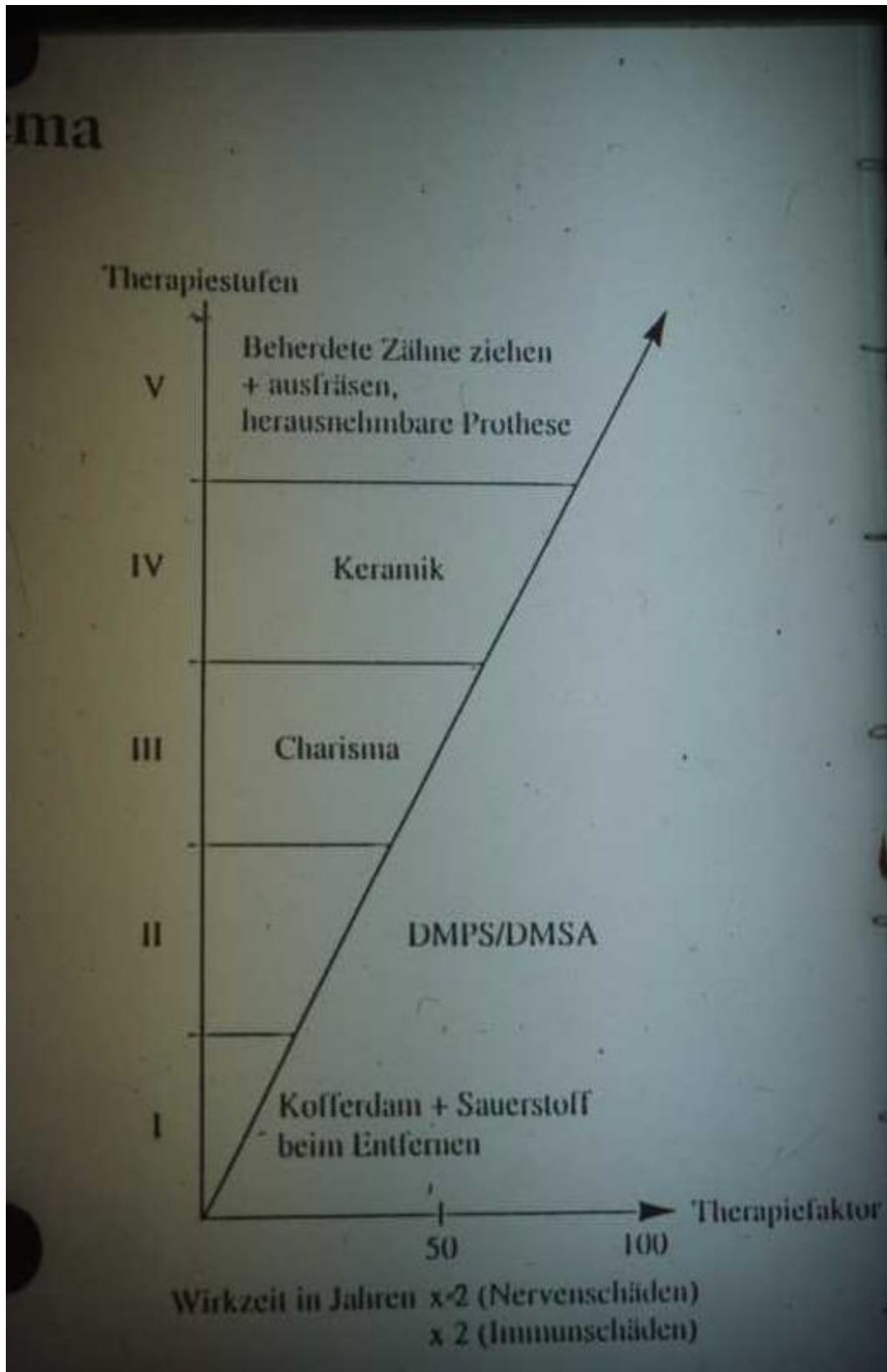


# Amalgam

Amalgam perlschnurartig um die Zahnwurzel

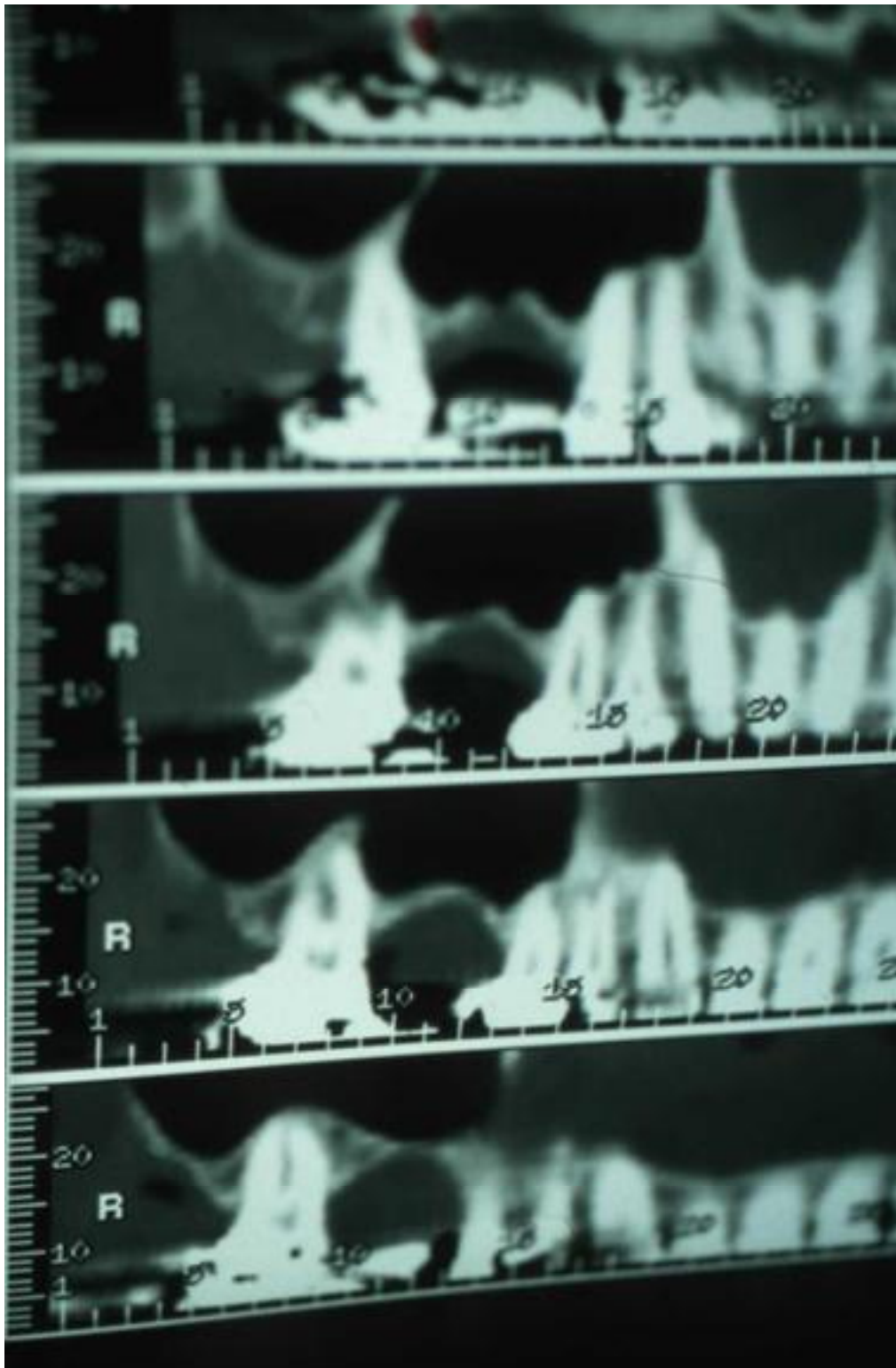


# Amalgam



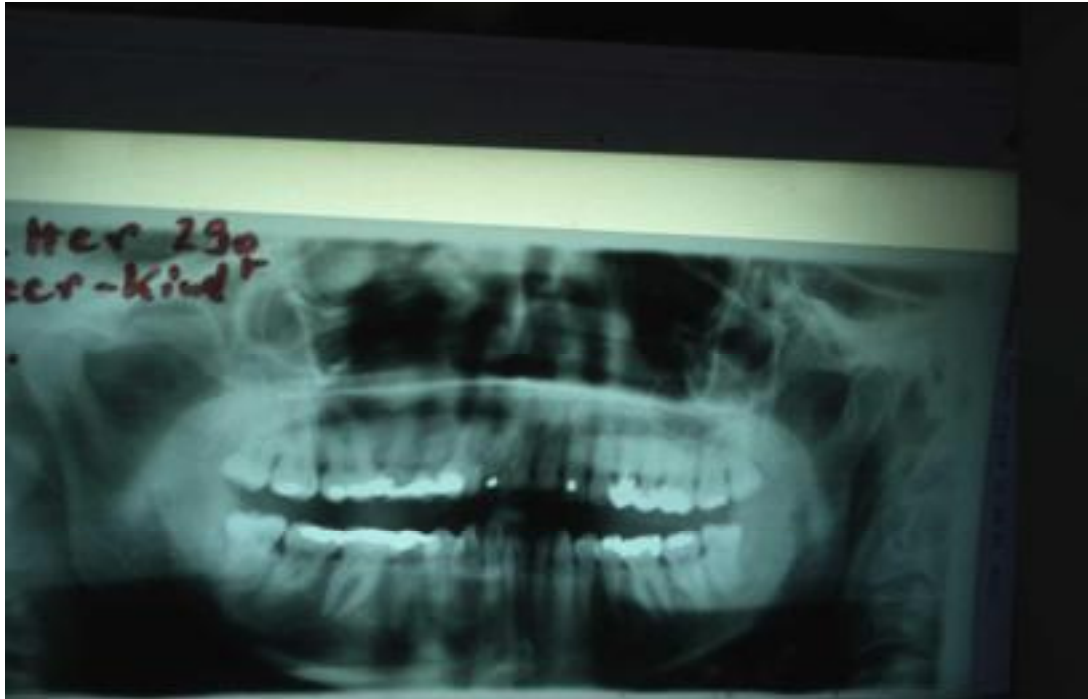# Amalgam

## Amalgam Zahnwurzel

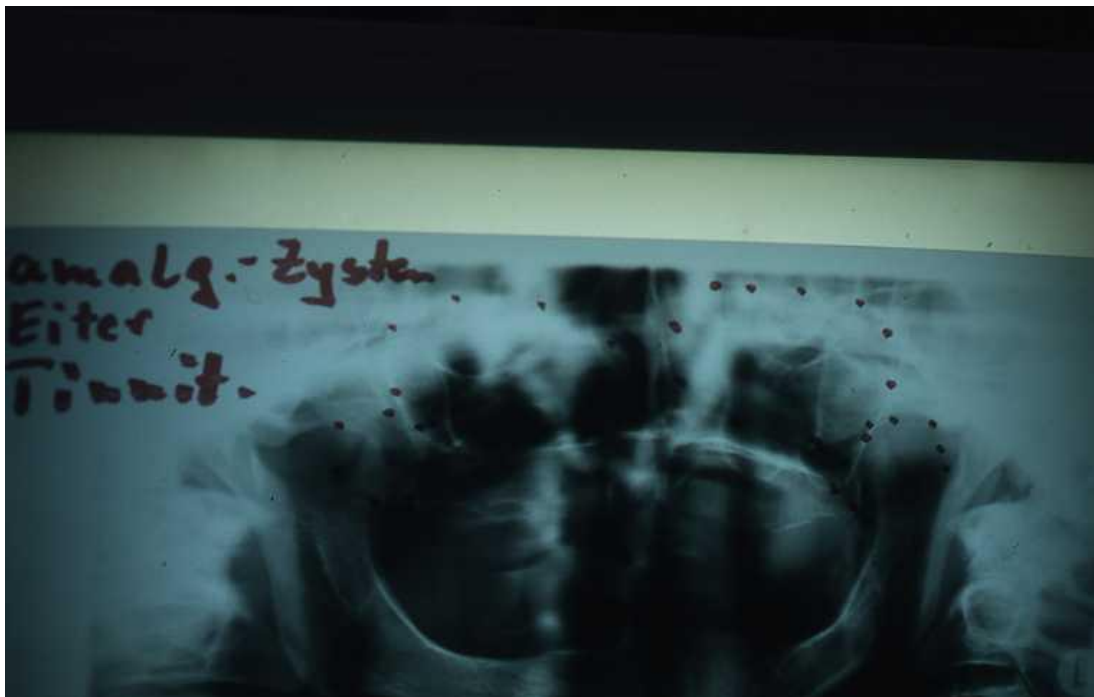


# Amalgam

Mutter, 29 Jhr., Feer-Kind

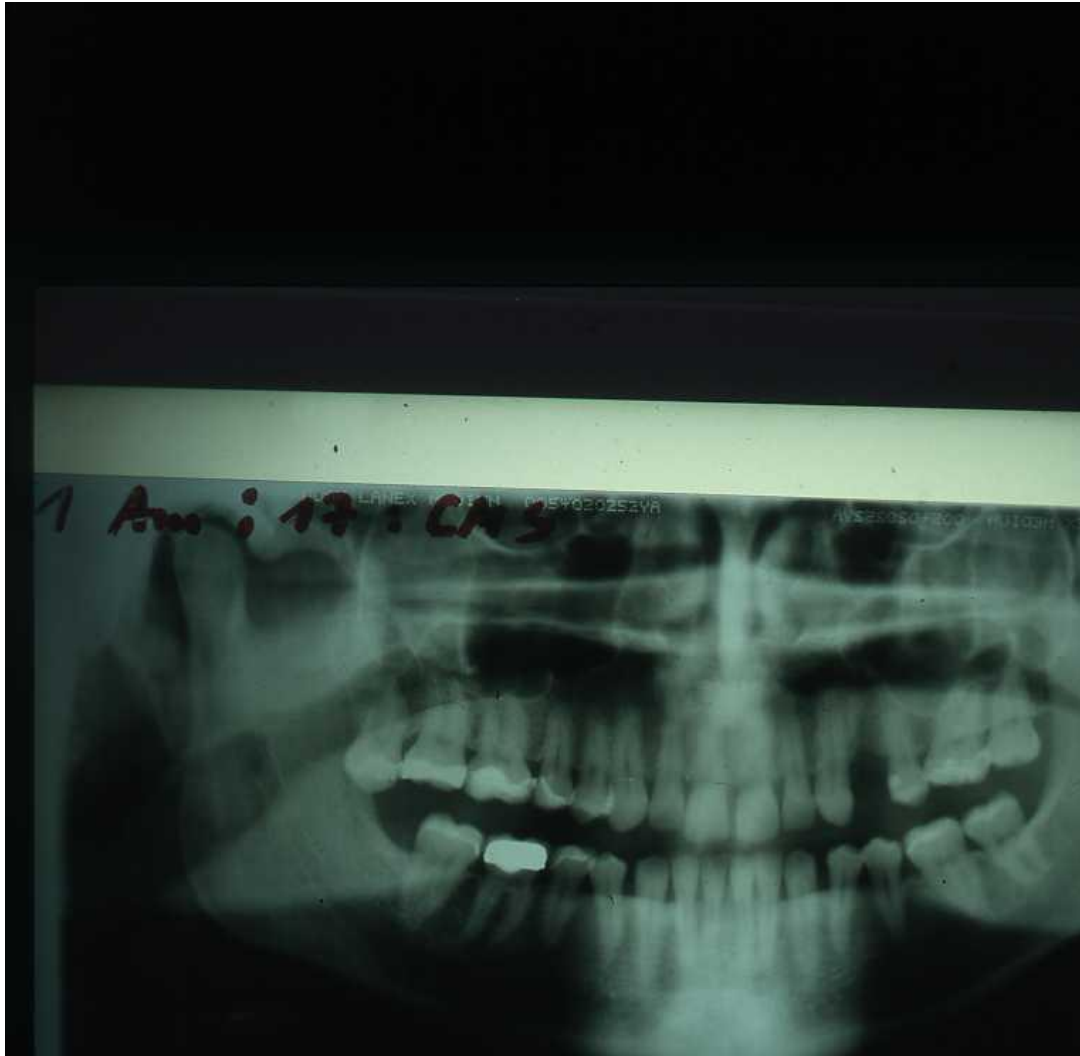

Amalgam-Zysten, Eiter

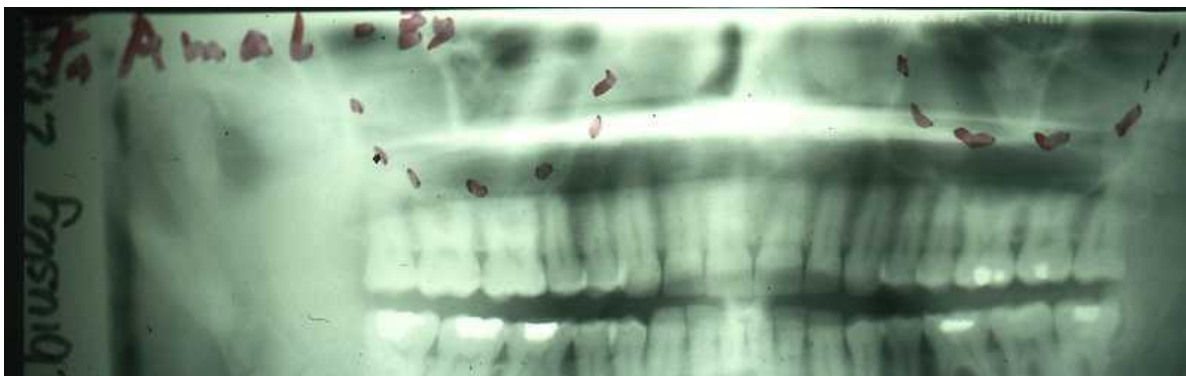


# Amalgam

1 Amalgam, 17 Jhr., Chronische Müdigkeit (CMS)

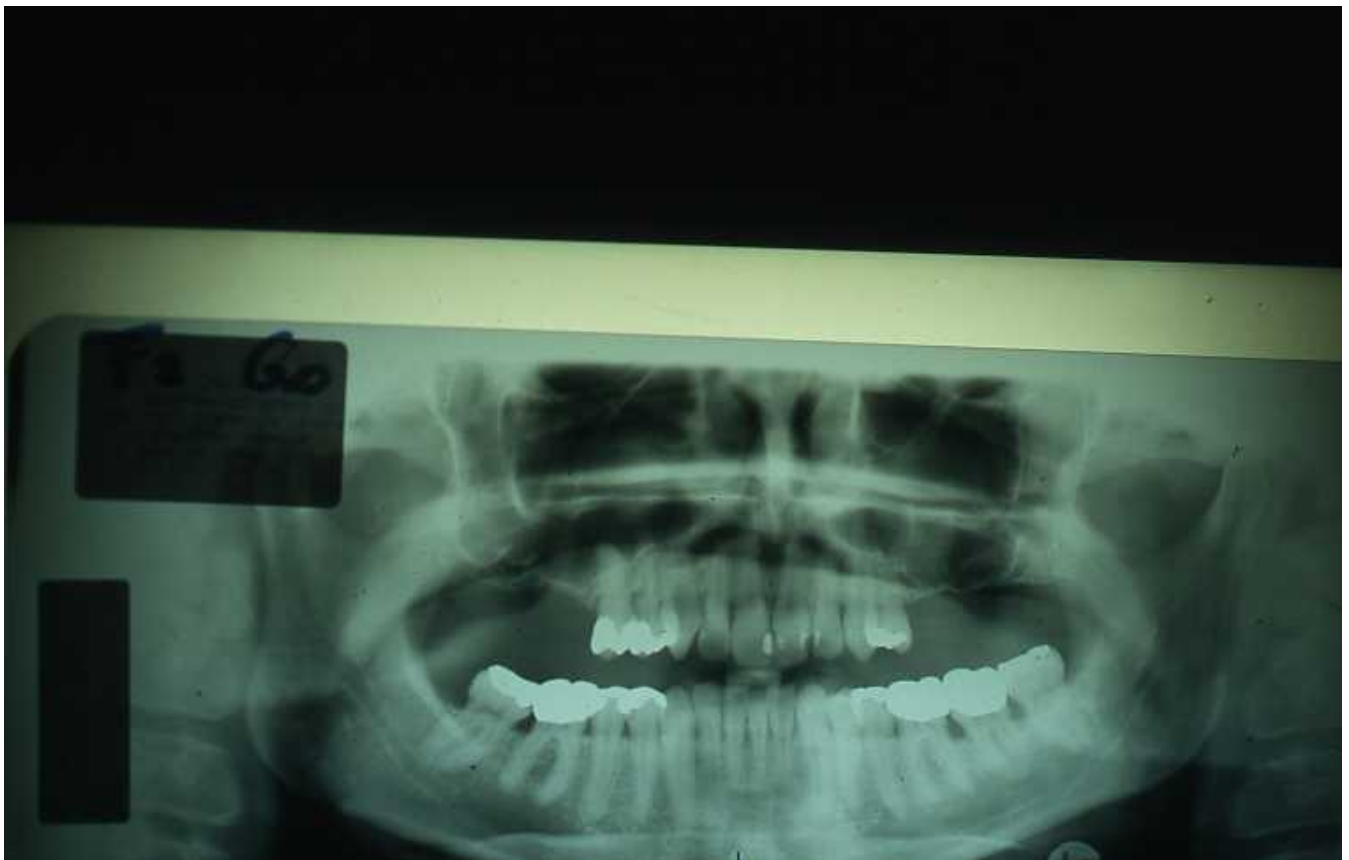
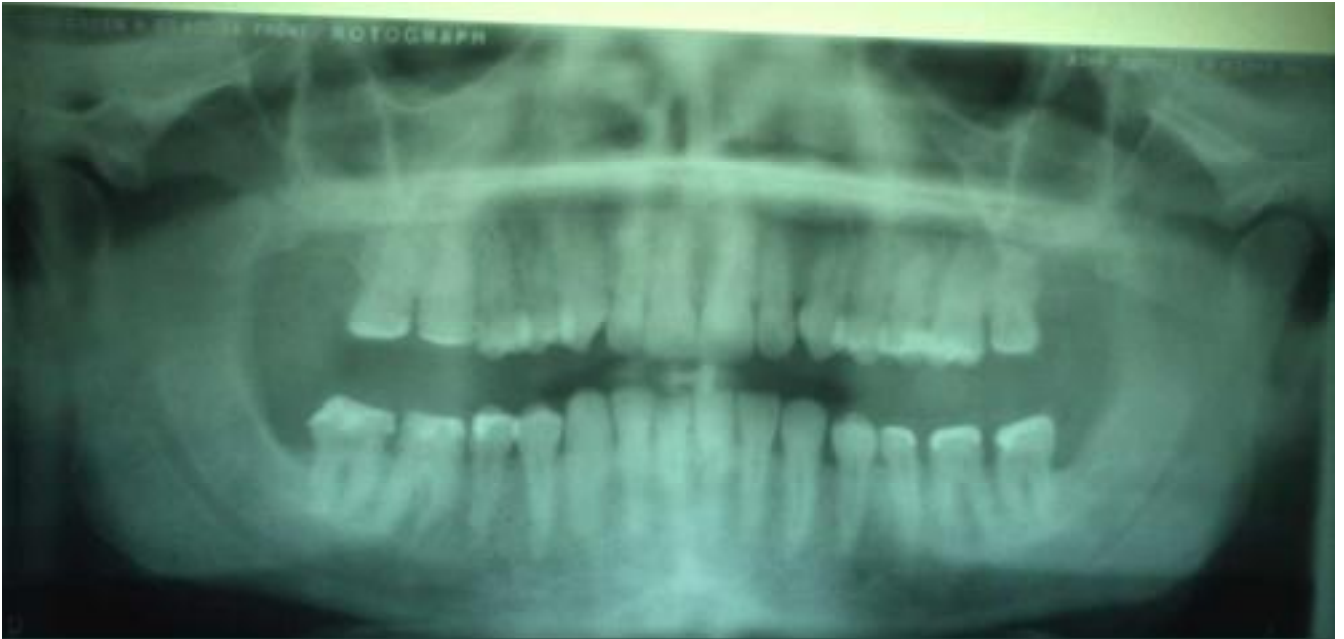
Amalgam-Zysten Oberkiefer



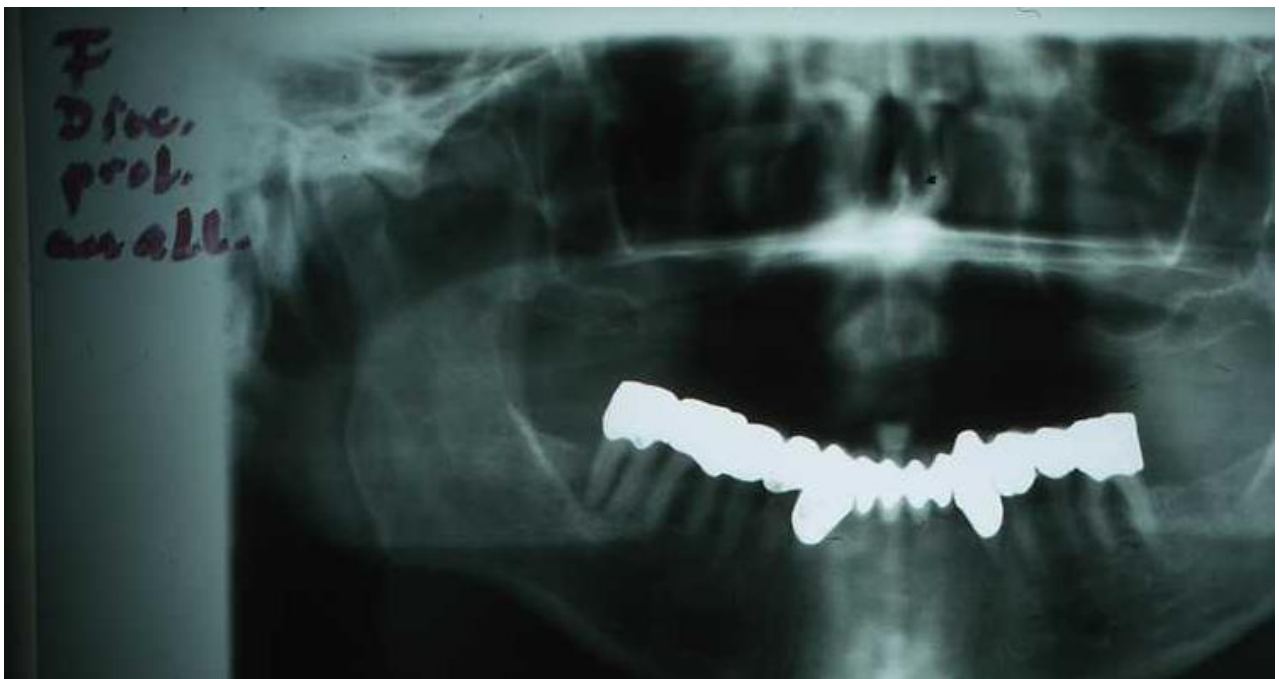
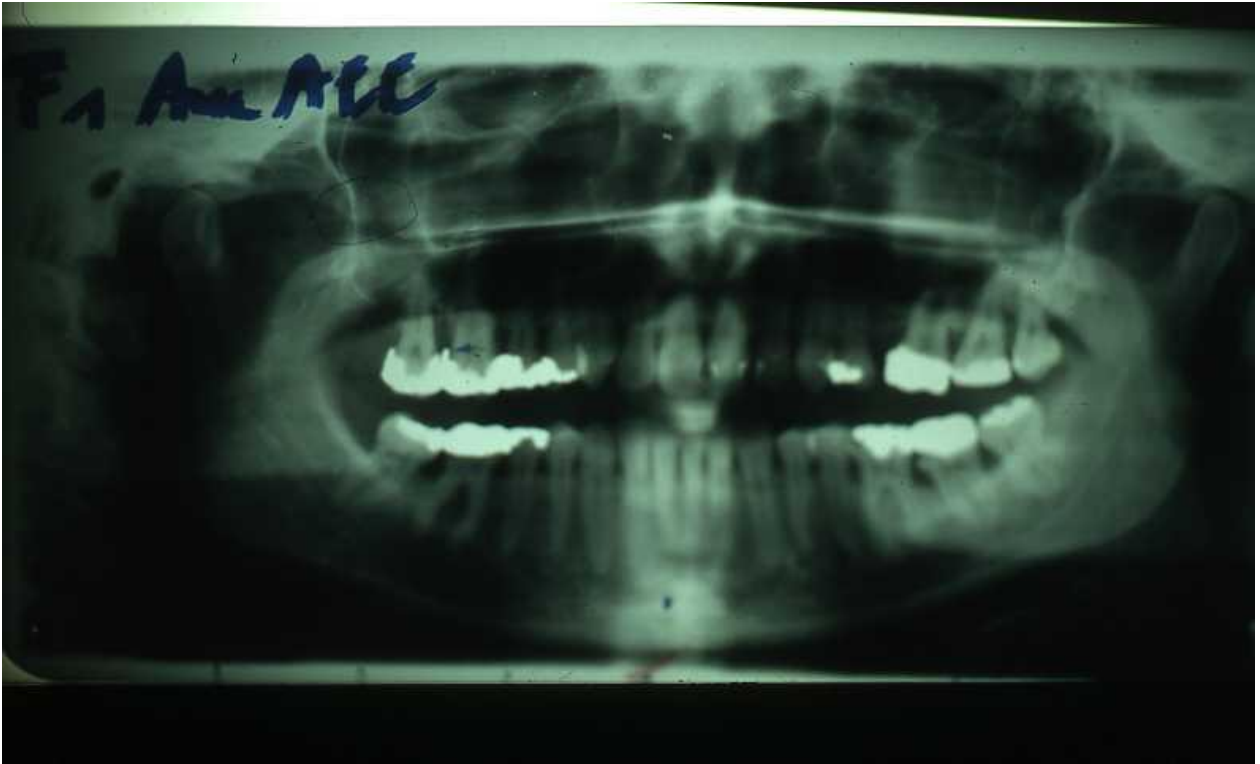
# Amalgam



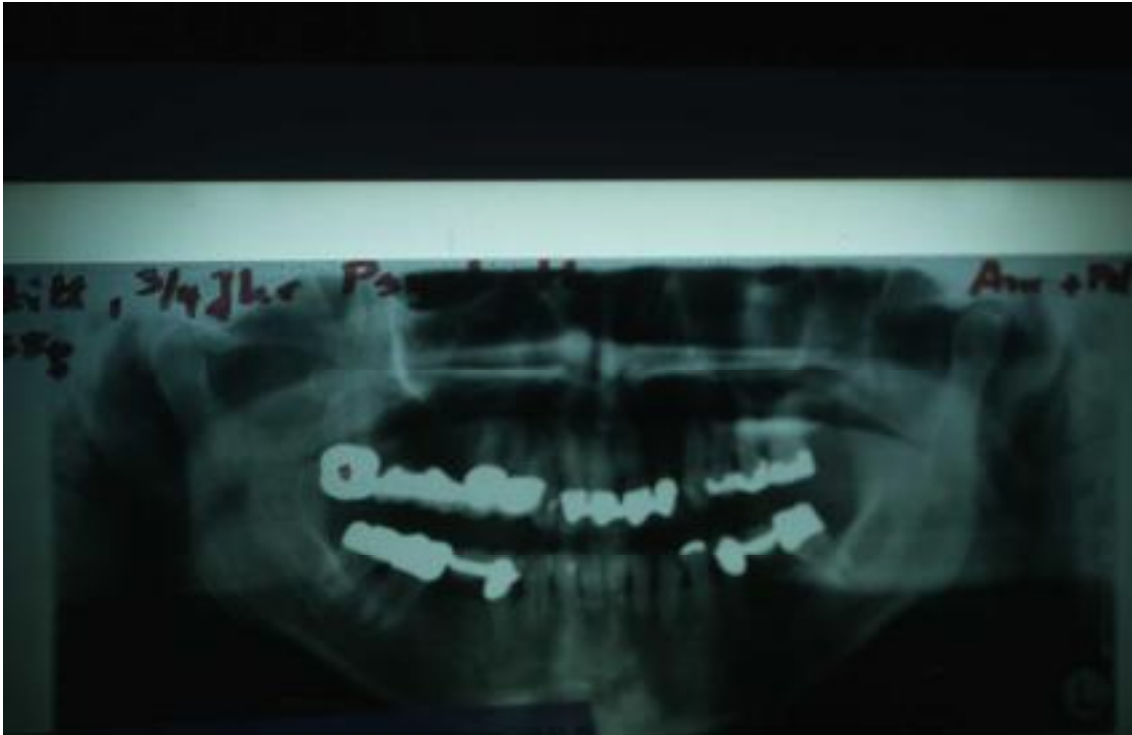# Amalgam

## Amalgamallergie

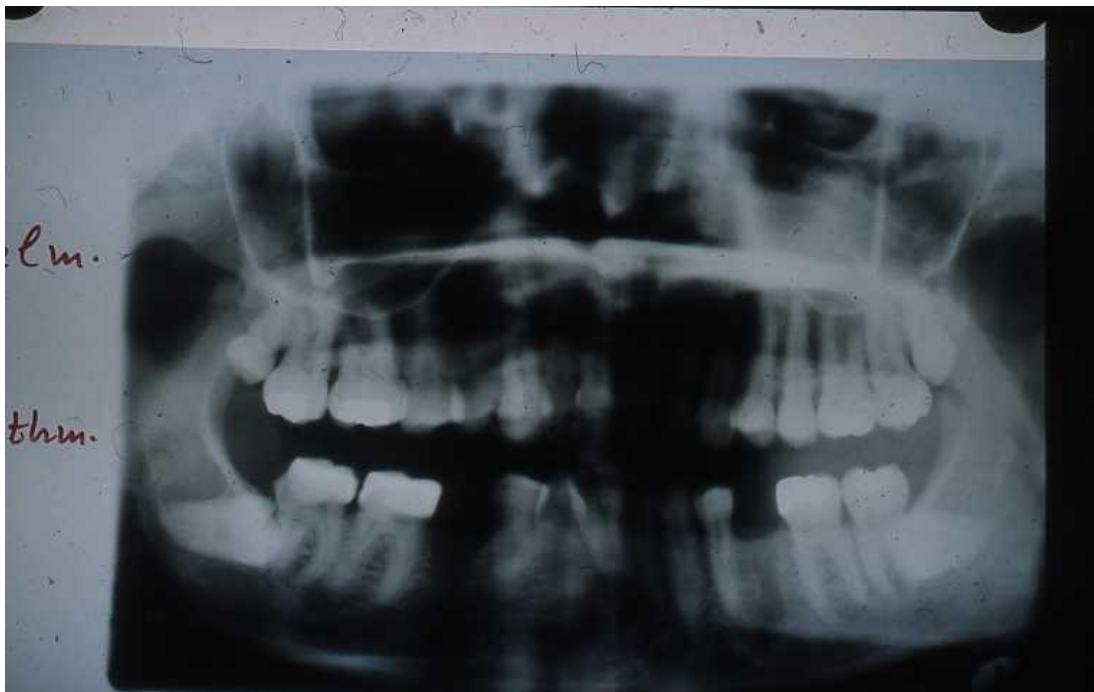

# Amalgam

Amalgam + Palladium,  $\frac{3}{4}$  Jahr Psychiatrie

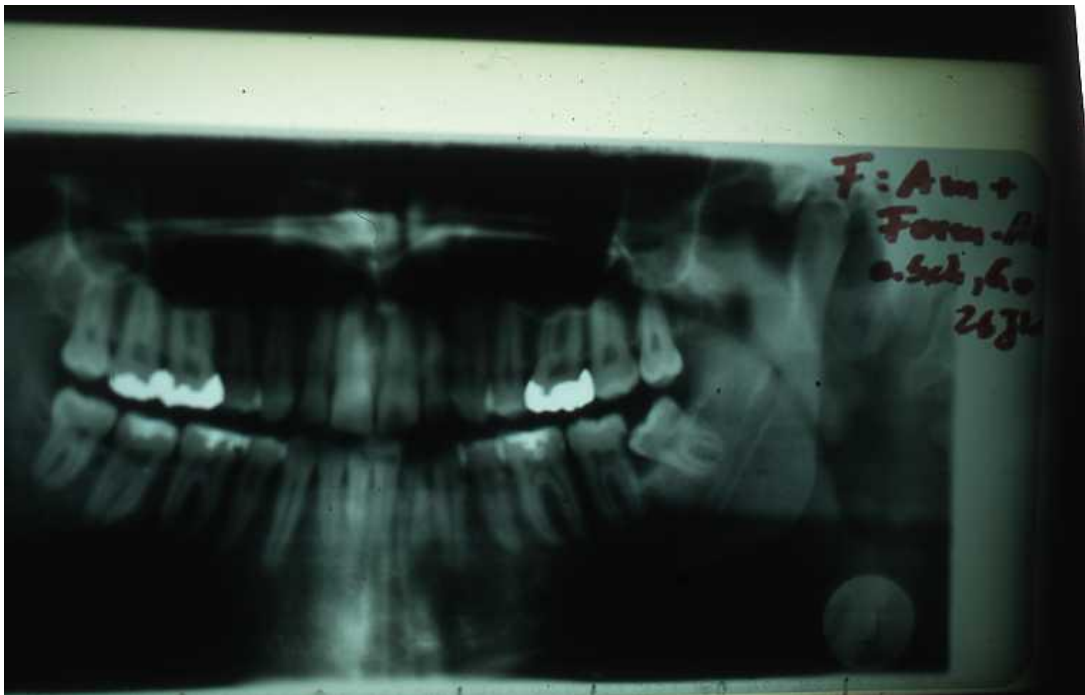
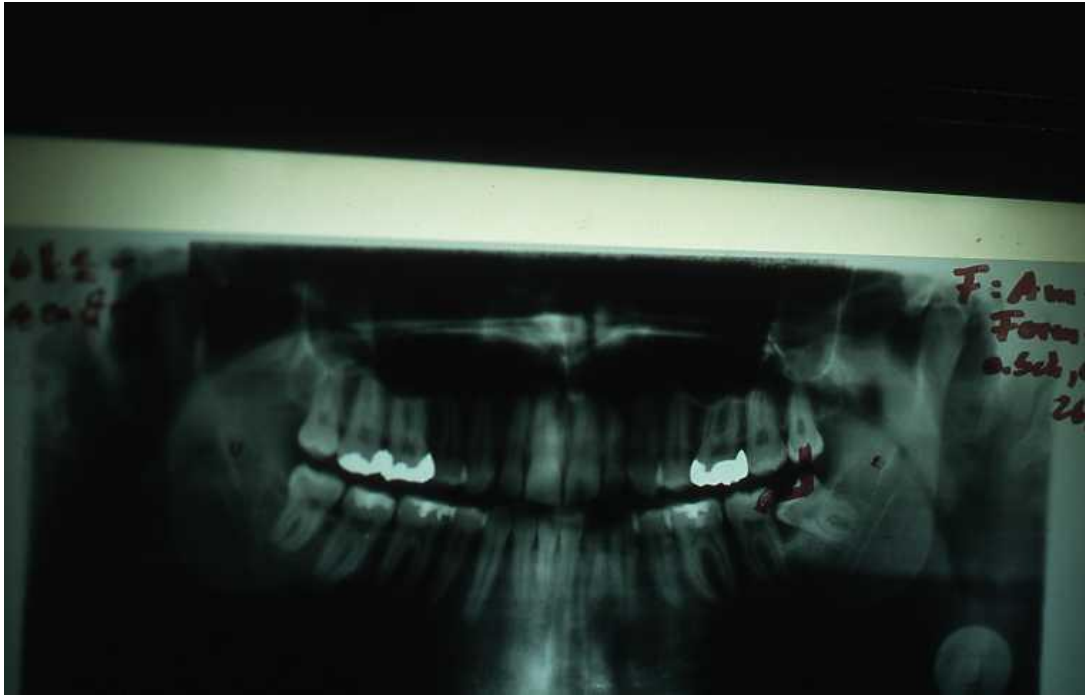


Amalgam + Herzrhythmusstörungen



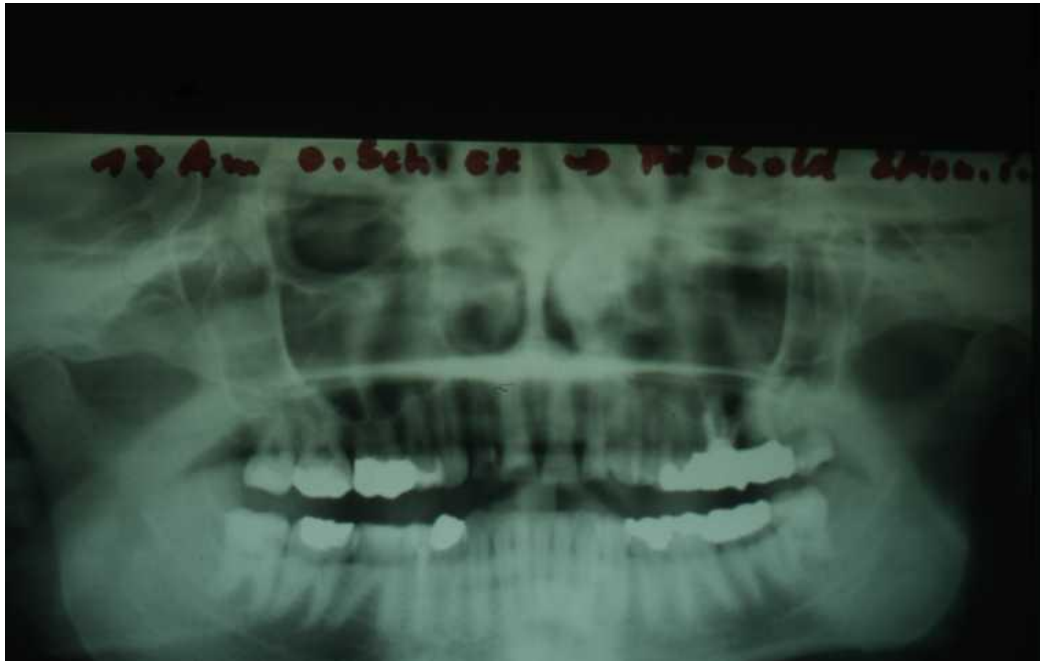# Amalgam

Fehler: Amalgam ohne Schutz entfernt, 26 Jhr.

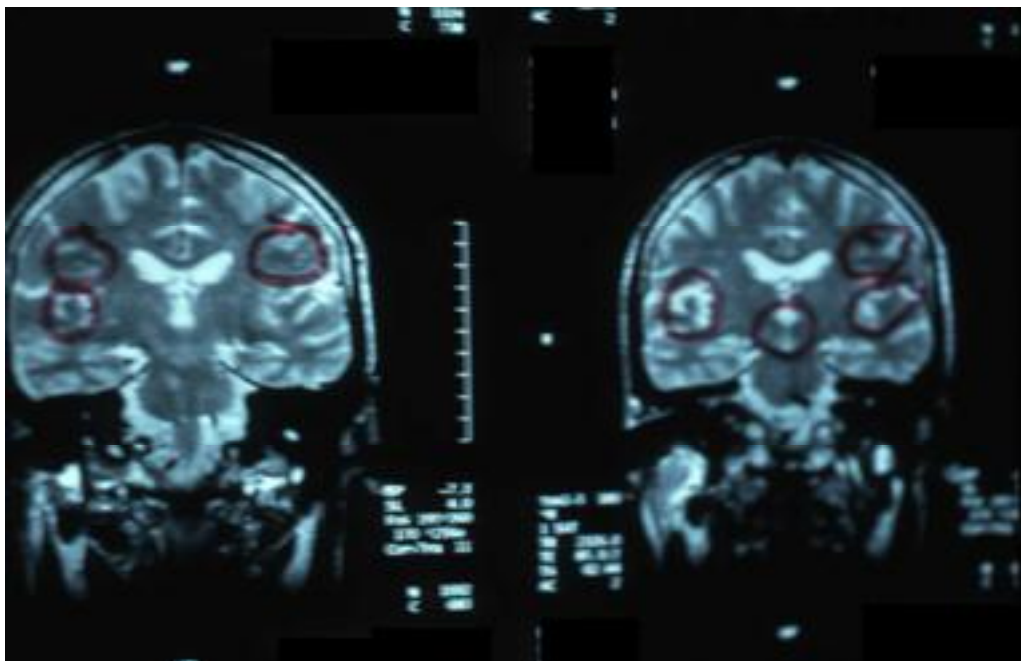


# Amalgam

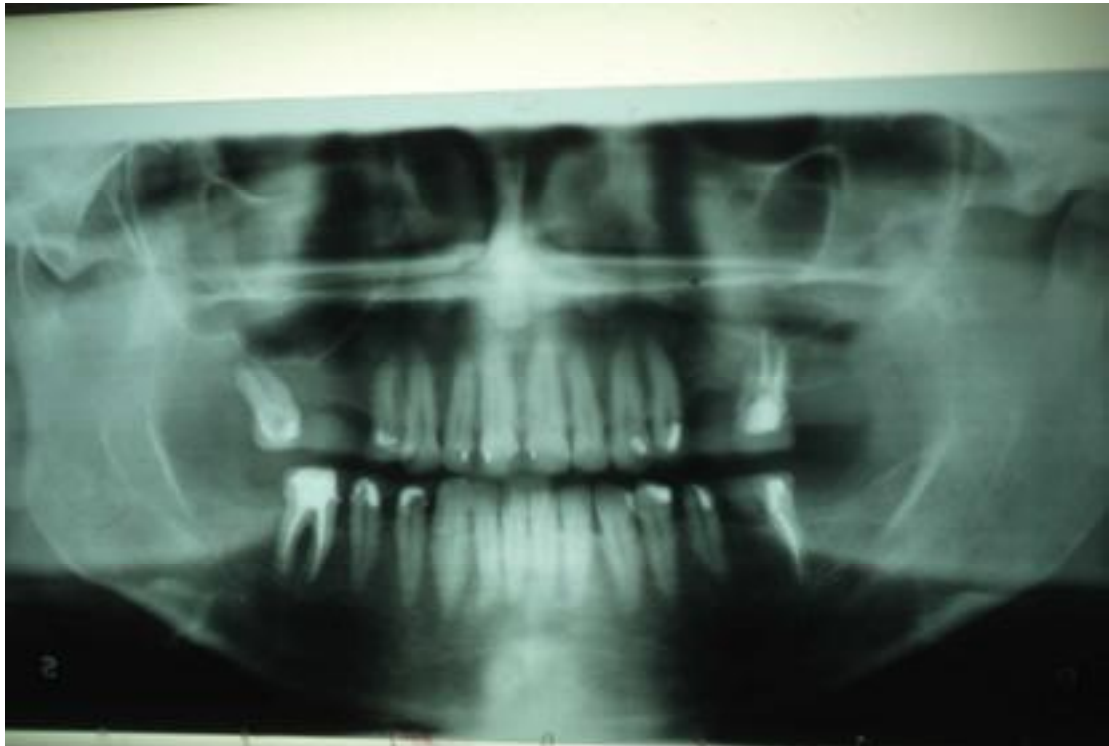Fehler: 17 Amalgame ohne Schutz entfernt, danach Palladium-Gold-Legierungen



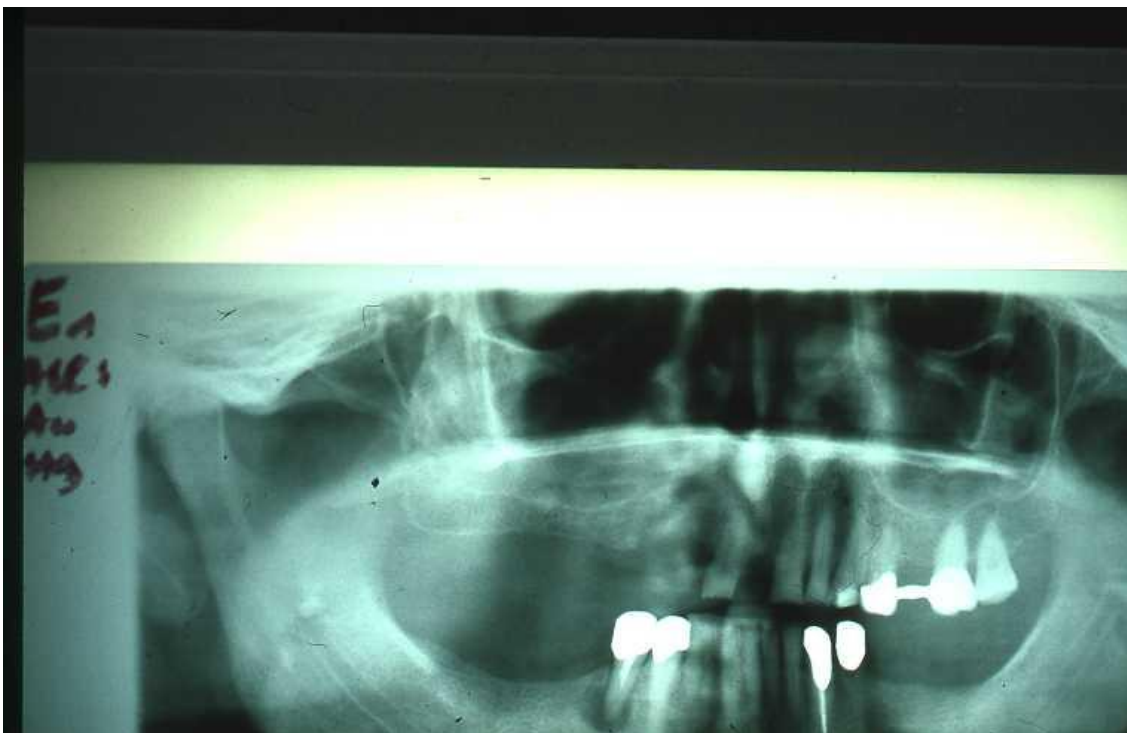
## Metallherde im Gehirn



# Amalgam

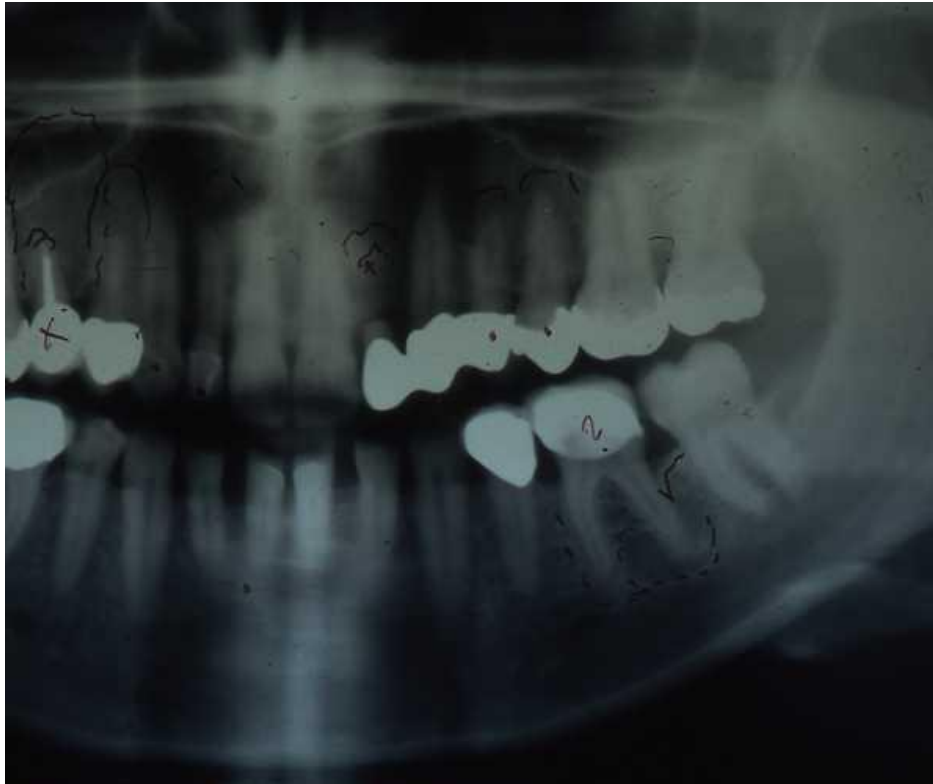


## Amalgam- und Goldallergie

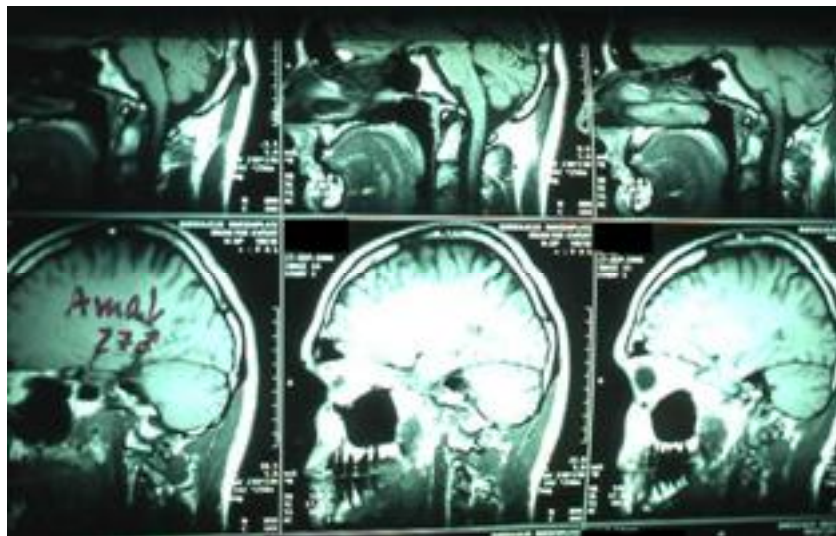


# Amalgam

## Amalgamreste an den Zahnwurzeln

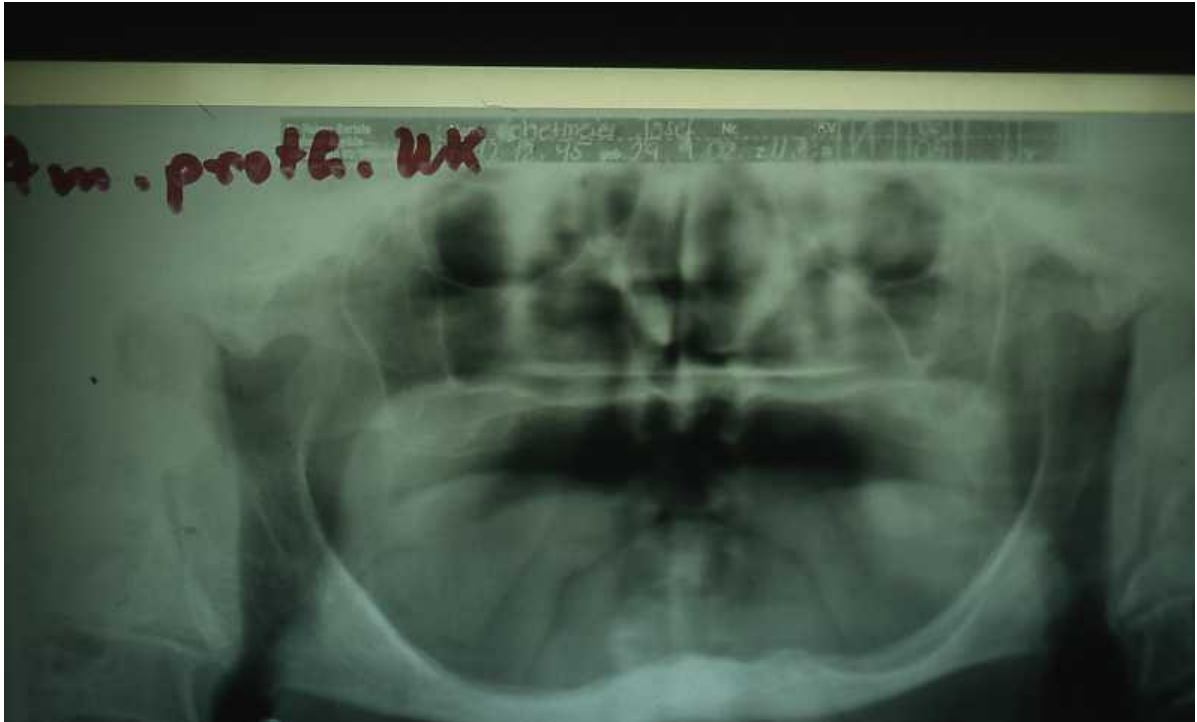


## Amalgam, 27 Jahre

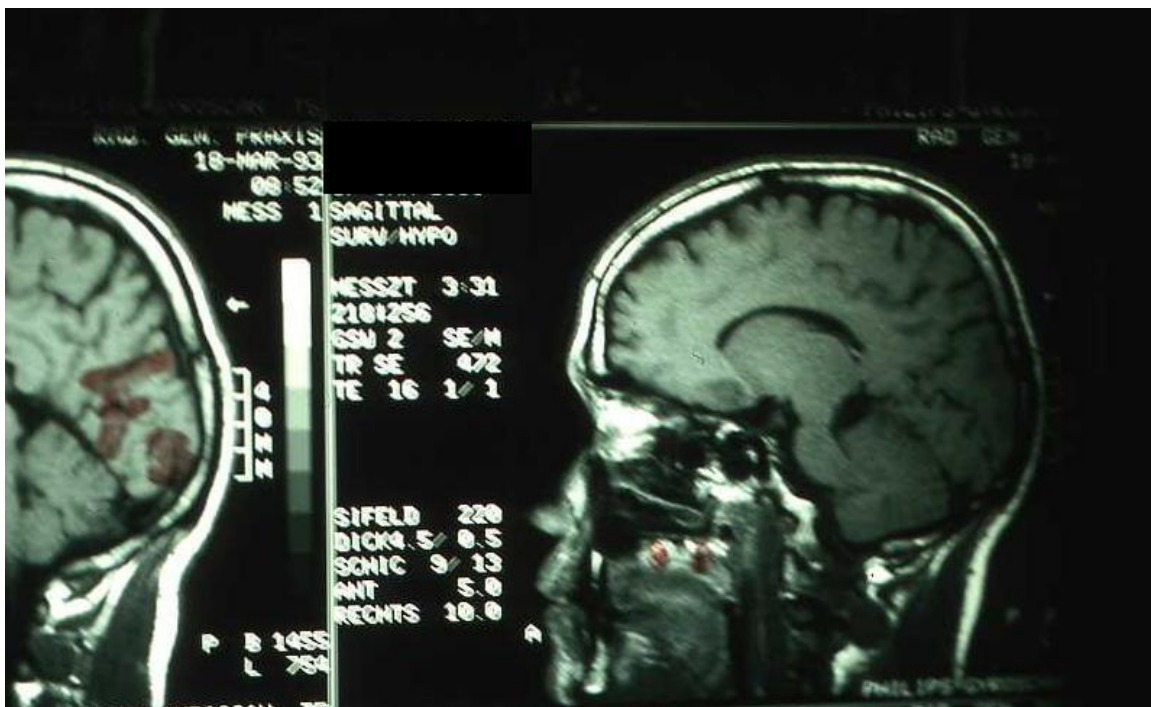


# Amalgam

## Amalgamprothese Unterkiefer



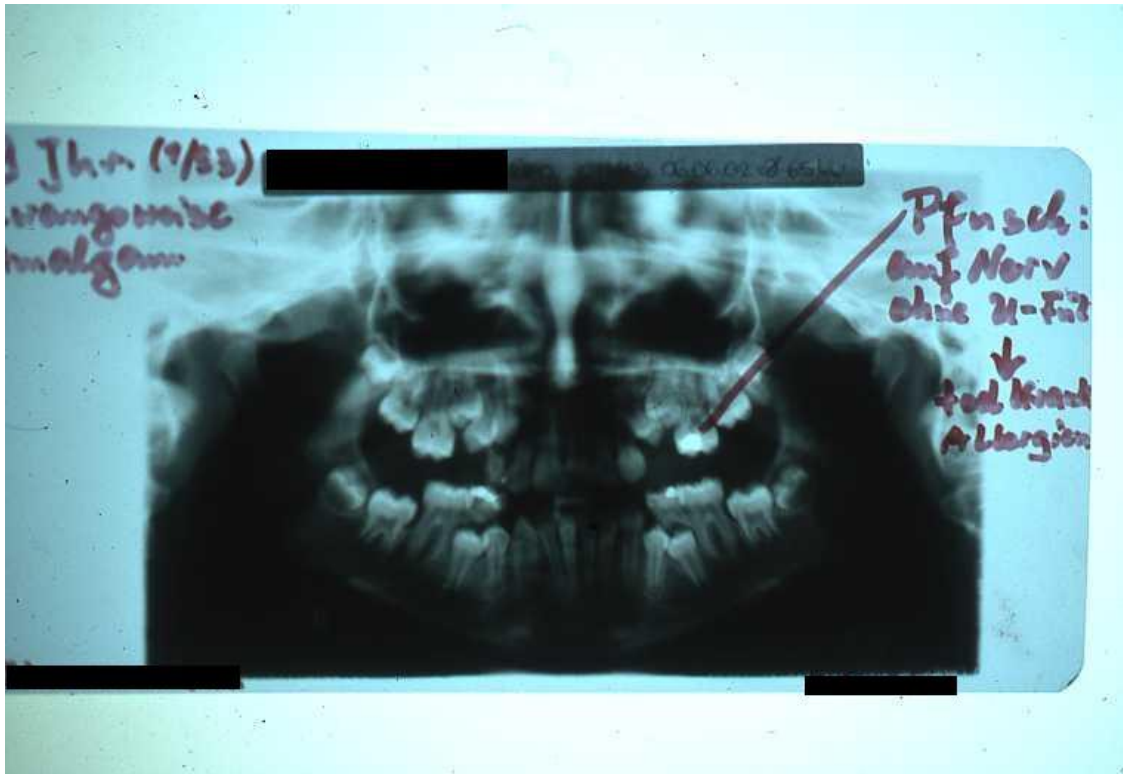
## Amalgamreste Oberkiefer





# Amalgam

**Pfusch: Amalgam ohne Unterfüllung auf Nerv gestopft –  
todkrank, Allergien**



**Amalgam in Milchzähnen trotz Widerstand der Mutter, 6 Jhr.**

