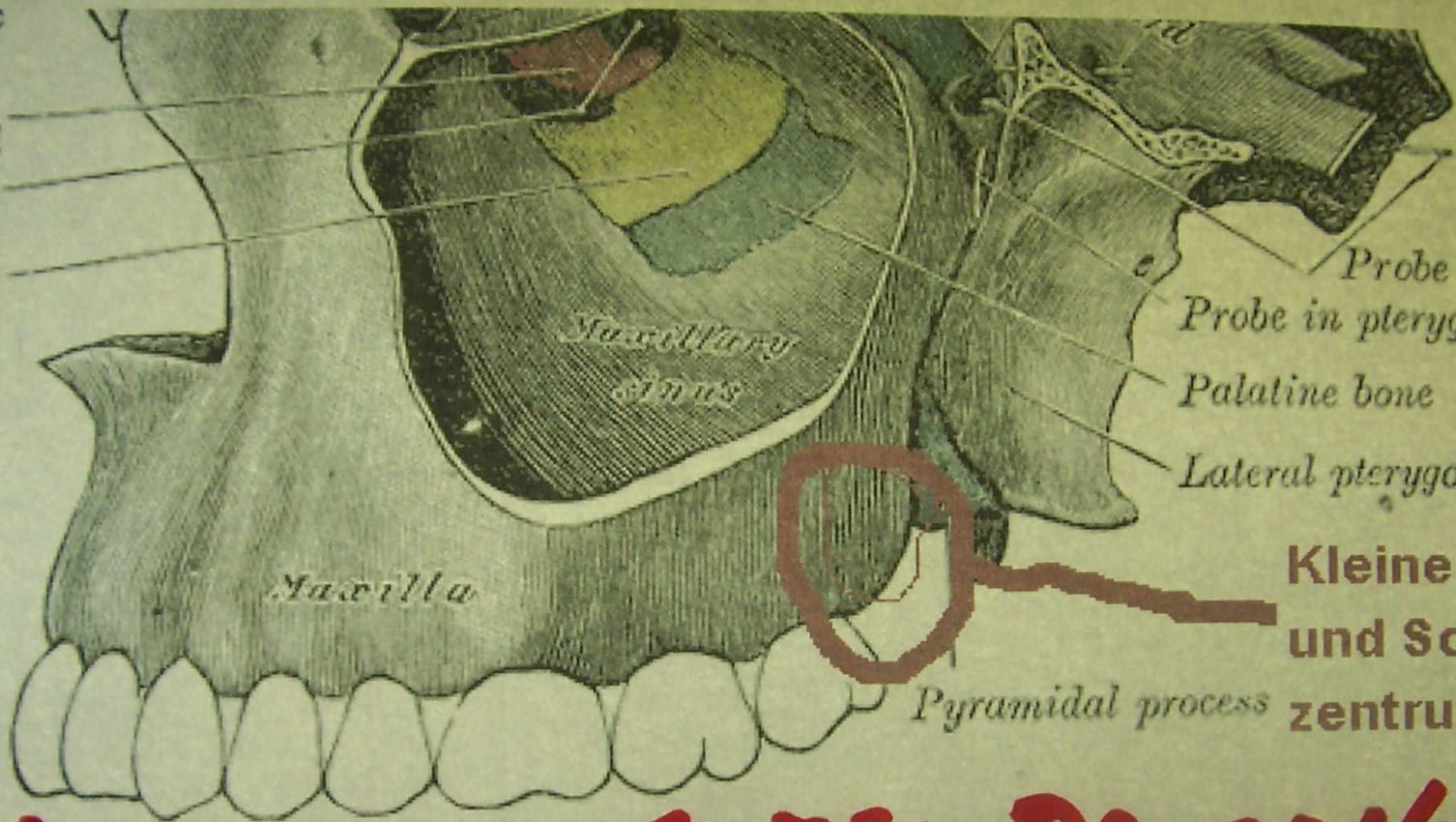


lacrimal sac  
pyramidal process  
of ethmoid  
laminae of  
maxillary sinus  
inferior nasal  
concha



Probe in pterygoid canal  
Probe in pterygopalatine canal  
Palatine bone  
Lateral pterygoid plate



**Kleine Schwellung  
und Schmerz-  
zentrum**

**5. Eiter kreft to the Dancethone**