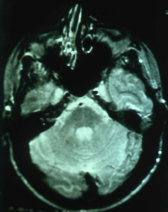


Zittern, Hörstörung,
amalgambedingtes Feer- Syndrom
Amalgam in Zahnfächern und
Nasennebenhöhlen



MR T1W AXIAL C1-C2

TR: 450.00
TE: 12.00
FOV: 230.00
S: 1.00
C: 1.00

1.00
0.00
0.00
0.00
0.00
0.00

0.00
0.00
0.00
0.00
0.00
0.00

0.00
0.00
0.00
0.00
0.00
0.00



MR T1W AXIAL C1-C2

TR: 450.00
TE: 12.00
FOV: 230.00
S: 1.00
C: 1.00

1.00
0.00
0.00
0.00
0.00
0.00

0.00
0.00
0.00
0.00
0.00
0.00

0.00
0.00
0.00
0.00
0.00
0.00



MR T1W AXIAL C1-C2

TR: 450.00
TE: 12.00
FOV: 230.00
S: 1.00
C: 1.00

1.00
0.00
0.00
0.00
0.00
0.00

0.00
0.00
0.00
0.00
0.00
0.00



MR T1W AXIAL C1-C2

TR: 450.00
TE: 12.00
FOV: 230.00
S: 1.00
C: 1.00

1.00
0.00
0.00
0.00
0.00
0.00

0.00
0.00
0.00
0.00
0.00
0.00

